

UDK 617.587-007.56-089

Diagnostics and Surgical Metatarsalgia Treatment

L.A.Gai, V.F.Venger, M.A. Saied and Parvej Singh*

Odessa National Medical University, Ukraine

Corresponding author: Parvej Singh; Parvejsingh87@gmail.com

Abstract

In this article were analyzed clinical, X-ray and sonographic results of the treatment taken by patients suffering for metatarsalgia. The said study involved 189 patients suffering from metatarsalgia (269 feet) who were divided into a core group that included patients suffering from metatarsalgia and patients having the same disease that was combined with hallux valgus and who underwent a surgery by using of the method developed by us (87 patients, 136 feet) and a control group which included patients suffering from metatarsalgia combined with hallux valgus and who underwent a surgery earlier by using of different techniques which goal was to correct hallux valgus (102 patients, 133 feet).

Keywords: diagnostics of metatarsalgia, metatarsalgia treatment, metatarsalgia treatment combined with hallux valgus.

So called “static deformations” of the foot make approximately one-third part in the structure of orthopedic pathology, wherein metatarsalgia is one of the main manifestations – that is a pain in interior compartment of foot. Exactly this pain in interior compartment of foot causes patients to see the doctor. The number of patients having this symptom made approximately 15% among an adult population of the USA in 1987 (Malay, Duggar). Hyperkeratosis under head of metatarsal bones points at the exact location of the pain, and an often combination of this state with a hallux valgus promoted the usage of such terms like “transverse platypodia”, “transversally-spread foot”, “transversally eagle-spread foot” (Anichkov N.M, 1995; Arzhannykova E.E, 1991; Dyvakov M.G., 1999; Ivchenko V.K., 2003, Levchenko V.O., 1999, 2001). It is worth mentioning that in modern classifications of diseases (for instance in ICD-10) a similar pathology is not mentioned.

Like it was explained by D.J. Morton in 1935, one of the reasons for existence of metatarsalgia was an absolute or relative shortening of the 1st metatarsal bone located under heads of the 2nd and 4th metatarsal bones. Subsequently,

this aspect of metatarsalgia pathogenesis was also explained by other authors (M.G. Dyvakov, 1999; Osochuk V.S. 2002; Rodgers M.M., 1989; Toth K., 2007) but any comprehensive impact assessment of anatomical forefoot structure concerning the origin and signs of metatarsalgia was not performed.

Fibrosis of subcutaneous fat along with microfractures of heads of metatarsal bones and degenerative damages of plantar plate of capsule of metatarsophalangeal articulation (MSA) (Yao L., 1994) are represented as an anatomical substrate of metatarsalgia (Studler U., 2008). A limited amount of research works dedicated to this issue disables to make final conclusions, however recent ultrasonographic and magnetic resonance studies show likely the biggest activity of plantar plate of metatarsophalangeal articulation (MSA) in the heart of a permanent metatarsalgia (McNelly Yu., 2007; Coughlin M.J. 1989; Yao L., 1994).

Unresolved issue is also the objectification of patient's complaints suffering from a metatarsalgia because visual, instrumental and X-ray anatomy features of structural abnormality of a forefoot may be asymptomatic (Harris R.I., 1949; Valdecker U. 2002; Walker M., 1998). In this regard is arisen the issue concerning the localization of anatomical structures which are responsible for a pain syndrome.

Some of methods represent the correction of hallux valgus as the leading moment and a part of them represent actually the said spreading (Hertsen G.I., 2004, V. Levchenko, 1988; Schemitsch E., 1989). At the same time and currently are used such non-physiological operations as a different type of a screed foot (Istomin I.S., 2000; Tserliuk B.M., 1991). By existing diversity of various operative methods the analysis of their effect on the severity and location of metatarsalgia was performed by single foreign searches (Glynn M.K., 1980; Mann R.A., 1992) as well as by some native authors (M.G. Dyvakov, 1999; Osochuk V.S., 2002). It was proposed that the forefoot's anatomical structure impacted the location and presence of metatarsalgia (Rodgers M.M., 1989) studied sporadically metatarsalgia dynamics in a surgical treatment of hallux valgus (Lindgren U., 1983; Wilson J.N., 1963)

Surgical treatment of metatarsalgia means actually a distal and proximal osteotomy of metatarsal bones (Helal B., 1984; Jarde O., 2001; Kitaoka H.B., 1994; Podskubka A., 2002) but they have specific complications such as a hypomotility of a metatarsophalangeal articulation (Podskubka A., 2002), as well as transferring the pressure to the adjacent metatarsal bone and discomfort by wearing tight shoes (Idusuyi O.B., 1998; Trnka H.J., 1996).

Thus, a number of unresolved issues of diagnostic and therapeutic nature determine the relevance of studying the problem caused by metatarsalgia.

The goal of a research work is to improve the results of surgical treatment of patients suffering from metatarsalgia which is based on the study of structural and functional changes in the forefoot caused by metatarsalgia and to develop the pathogenetic mean for a surgical treatment.

Materials and Methods

The results of observation of 189 patients suffering from metatarsalgia (269 feet) were used as the material for the further research work. The studied group consisted of patients with metatarsalgia and metatarsalgia combined with hallux valgus and who were operated by applying a method developed by us (87 patients, 136 feet), and a control group consisted of patients who had hallux valgus combined with metatarsalgia and who were previously operated by using of various techniques aimed at correction of hallux valgus (102 patients, 133 feet).

Were used clinical and radiological, ultrasonographic, biomechanical and statistical methods.

A full orthopedic examination of the patient along with a detailed foot examination were also performed – such like complaints of pain, its severity, location, ratio of relative lengths of the 1st and 2nd metatarsal bones, the presence and localization of callous areas on a plantar surface of the foot. The amount of movements was calculated by a 0-pass method. The presence of a pain syndrome and its dynamics during the treatment was assessed by using a visual analog scale (VAS). The activity of foot before and after surgery was evaluated by using

Results of the treatment were assessed in accordance with a quantitative evaluation scheme recommended by American Orthopaedic Foot and Ankle Society (AOFAS).

The relatively short first metatarsal bone was marked as 1 Sq. (-), “Zero”, the 1st metatarsal bone was marked as 1 Sq. (0) and relatively long the first metatarsal bone was marked as 1 Sq. (+).

Calculations of radioanatomic indicators were carried out in accordance with feet stress radiographs shown in a frontal projection and angles were measured as follows: a metatarsophalangeal angle (MSA) is the angle located between the 1st metatarsal bone and the main phalanx of the 1st toe; 1-2 intermetatarsal angle (1-2 IMT) is the angle located between the 1st and 2nd metatarsal bones; intermetatarsal angle 1-5 (1-5 IMT) is the angle located between the 1st and 5th metatarsal bones; 4-5 intermetatarsal angle (4-5 IMT) is the angle located between the 4th and 5th metatarsal bones (Fig.1).

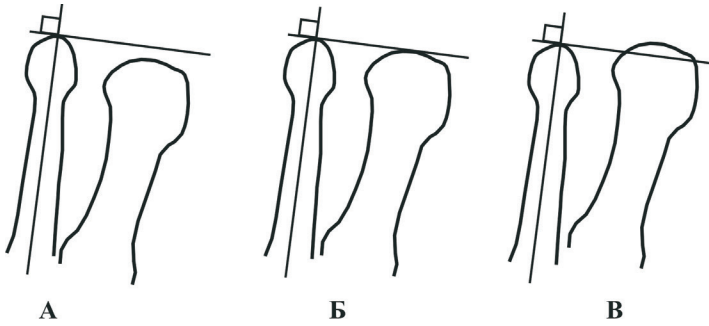


Figure 1

These figures and other data were shown in spreadsheets and for angle parameters was used a descriptive statistics (that is a mean, standard error). Significance of the difference was determined by using a double selective Z-test for a secondary and a paired T-test for medium. The results of measuring the relative length of the 1st metatarsal bone was evaluated by χ^2 -test. All calculations were performed by using a Microsoft Office Excel 2007 software and by using the built-in STATISTIKA v. 5.5 software package (firm producer: Star Soft Inc., USA).

An ultrasound examination was performed with application of HDI-3500 (USA) device by using a linear multifrequency sensor with a frequency range of 7-12 MHz. Qualitative and quantitative characteristics of plantar tissues of the foot surface were examined in 14 patients having metatarsalgia located under heads 2-4 of metatarsal bones (in total 53 metatarsophalangeal articulations). A comparison group was created from 10 healthy persons who had no visual signs of any foot pathology and who had no complaints. The 2nd metatarsophalangeal articulations on both feet of these persons were examined (all together were carried out 20 studies). The study was performed in longitudinal and transverse positions in the B-mode. In a longitudinal position of the sensor were evaluated the quality characteristics: i.e. smoothness and sharpness of contours of a cortical plate of a plantar surface of a proximal phalanx as well as the head of a metatarsal bone; quantitative characteristics – i.e. the thickness of the plate at the level of head of a metatarsal bone. Lateral position of the sensor enabled to detail the damage of a plantar plate. Unified standards for echosemiotics such like echogenicity, sizes, uniformity of structure (homogeneity), sharpness of interfaces and smoothness of contours were applied by evaluation of the image.

Results of treatment of patients suffering from metatarsalgia. Errors and complications.

The results of treatment were evaluated for 71 feet of 62 patients who were in the main experimental group and for 133 feet of 102 patients who were in the control group. As evaluation criteria were used scores of a scale approved by American Orthopaedic Foot and Ankle Society (AOFAS) as well as an intensity of a pain syndrome (VAS).

In the main experimental group the integrated assessment of the functional ability of the foot before a surgery made up 64 points and after a surgery it made up 91 points. The corresponding figures for patients in the control group made up 62 and 74 points. As can be seen, the initial levels of functional ability of the foot were not different that proves the correct comparison of the experimental and control groups (Fig. 2).

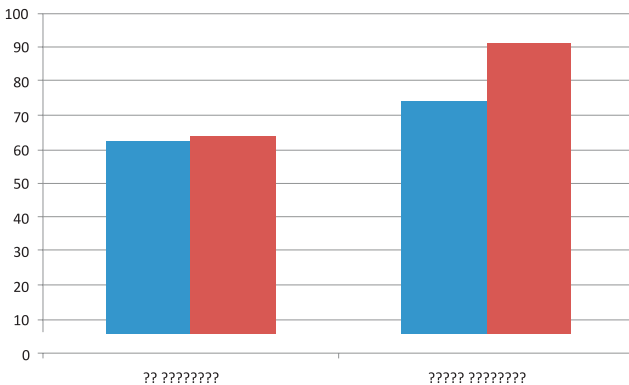


Figure 2

Severity of a pain syndrome by patients of the experimental group was assessed in all cases and separately for patients who had no complications. The total assessment showed a reduction of a pain from 5.4 up to 1.1; and by patients who had no complications it showed from 5.2 up to 0.7 (a paired t-test for medium, $p < 0.05$).

Patients in the control group had a total assessment which showed a decrease in a pain syndrome from 5.7 up to 2.3 (a paired t-test for medium, $p < 0.05$). Therefore, we developed a correction method for hallux valgus in relation to metatarsalgia which proved an effective metatarsalgia treatment.

In addition, the application of a new method of a surgical metatarsalgia treatment enabled to increase the effectiveness of metatarsalgia treatment, and namely to increase by 17% successful outcomes and to reduce for 5-7 days

the patient's stay in the hospital as well as to shorten the period of disability of patients suffering from metatarsalgia approximately by 3-4 weeks.

In 5 cases which made up 7% of the total amount of feet operated were noticed further complications. The latter were revealed in superficial surgical infection (2 feet) and hematomas in postoperative wounds (3 feet). Surgical infection was cured by mean of continuation of a general antibiotic treatment and through a local relevant treatment while hematomas were drained.

Long-term complications became evident due to presence of metatarsalgia in a previous location, an incomplete disappearance of metatarsalgia and its further dislocation - only 13 cases. Incomplete disappearance of metatarsalgia was noticed in 6 cases with a preoperative localization under heads 2-4 of metatarsal bones, they all were caused by the rupture of a "tendon reins" and, consequently, by decrease of a corrective transposition effect. The presence of a metatarsalgia "dislocation" requires a further research.

The most interesting and quite unexpected was a complication that became evident in the form of metatarsalgia dislocation under head of the 5th metatarsal bone by a preoperative localization under head of the 1st metatarsal bone. In these cases was noticed an increase in values of 4th-5th metatarsophalangeal bone.

A small number of these complications disables to make definitive conclusions about the mechanism of metatarsalgia dislocation but uniformity of some changes attracts our attention. First of all, this permanent ideal correction of a metatarsophalangeal bone and the 1st and 2nd intermetatarsal bone which confirms the reasonability for the use of transposition of the 1st finger profundus tendon for a treatment of hallux valgus.

Secondly, and this would be fair not only for discussion of the cases of metatarsalgia dislocations, but also for the entire experimental group, that after the surgery performed the position of 2-5 fingers was shown on radiographs in a reduction position. It is impossible to say for sure if this was the effect caused by the 1st finger profundus tendon, or one of common tendons of the 2-5th fingers, or it was their combined effect. But such a powerful effect of dislocation on X-ray features of the forefoot requires a further research and may become a promising way to correct other orthopedic pathology of the foot.

And finally in all these cases was noticed a slight increase of the 4-5th metatarsophalangeal bones after such surgeries were performed and it is impossible to estimate this by such research.

Conclusion

On the basis of X-ray and ultrasound anatomical features of the forefoot was proposed a scheme that was clinically tested for diagnosis and treatment of patients suffering from metatarsalgia. A new method of surgical metatarsalgia treatment helped to solve urgent task to improve the results in metatarsalgia treatment.

1. Metatarsalgia has been characterized by pain in interior compartment of foot and has certain structural features that reflect three options for its location: at the head of the 1st metatarsal bone (19% of cases), under the metatarsal heads of the 1-2 metatarsal bones (4% of cases), under the heads of the 2-4 metatarsal bones (77% of cases). Angle indicators of the forefoot don't affect the localization of metatarsalgia.
2. Localization of metatarsalgia depends significantly on the relative length of the 1st metatarsal bone, in particular, the relative shortening of the 1st metatarsal bone is combined with a metatarsalgia localization under the metatarsal heads of 2-4 bones, and never depends on other localizations (χ^2 -test, $p < 0,001$).
3. Dynamics of the pain syndrome caused by surgical treatment was significantly dependent on the elongation of the 1st metatarsal bone.
4. By performance of ultrasonographic examinations was revealed that degenerative changes in plantar plate of a metatarsophalangeal articulation are the reasons for metatarsalgia existence.
5. Method of surgical treatment of patients suffering from hallux valgus and metatarsalgia developed on the basis of theoretical calculations provides the correction of metatarsophalangeal angle and promotes the elongation of the 1st metatarsal bone and reduces the pressure of a plantar surface under heads of relevant metatarsal bones.
6. The application of a pathogenetically substantiated method of surgical metatarsalgia treatment contributed to the improvement of the foot activity from 64 up to 91 points by patients treated in the main experimental group whereas the physical activity of feet by patients of the group was improved from 62 up to 74 points (as per a AOFAS scale).

Literature used

1. Venger V.F. Serduk V., Gai L., Hurienco A., G. Slavov G.G. 2004 “Open treatment of hallux valgus (surgical classification of methods)” // *Marine Medical Journal*. **4**(27): Pages 62-73
2. Gai LA, Venger V.F., V.V. Serdiuk 2004. “Surgical treatment of hallux valgus at 1st- 2nd stage of disease”// *Odessa Medical Journal*, **3**(83): 43-46
3. Gai L.A., Venger V.F. Serdiuk V.V. 2005. “Concerning the issue of etiopathogenesis hallux valgus” (historical sketch)// *Odessa Medical Journal*. **1**(87): 101-104 (Bibliographic analysis)
4. Gai L.A., Venger V.F. 2009. “Surgical metatarsalgia treatment”// *Marine Medicine Journal*. **2**: 79-85
5. Gai L.A. 2010 “Diagnosis and surgical metatarsalgia treatment” (Review of literature)// *Orthopedics, Traumatology and Prosthetics Journal*, **1**: 79 - 82
6. Venger V.F. Gai L.A. 2010. “Transposition of m.extensor digitorum tendons by treatment of patients suffering from metatarsalgia”// *Journal of orthopedics, traumatology and prosthetics*. **2**: 47-49
7. Levchenko V.A. 1988. “Myotenoplastical correction of a cross-splitted foot”// Abstract. PhD thesis ...: 14.00.22. - K., P. 24
8. Liabakh A.P. 2003 “Clinical diagnosis of talipeses” - Kyiv: Atlant UMC CJSC – P. 43
9. Serdiuk V.V., Gai L.A. Licence of Ukraine No 47 338 UA. МПІК А61В 17/52. “The method of surgical hallux valgus treatment in the initial stages of deformation and 2001128915”; Application 21.12.2001; Published on June 17, 2002, Bulletin No 6