



Gross Anatomical Features of the Tongue of Blue and Gold Macaw

Prashant M. Gedam^{1*}, Yousuf Dar¹, Aditya Kumar¹, Naresh Chandra² and Prabhakar Kumar¹

¹Department of Veterinary Anatomy, COVAS, Sardar Vallabhbhai Patel University of Agriculture and Technology, Meerut (UP), INDIA

²Department of Veterinary Clinical Complex, COVAS, Sardar Vallabhbhai Patel University of Agriculture and Technology, Meerut (UP), INDIA

*Corresponding author: PM Gedam; E-mail: pm.gedam06@gmail.com

Received: 03 Feb., 2022

Revised: 19 March, 2022

Accepted: 24 March, 2022

ABSTRACT

In the present study, the tongue was found to be a part of the lingual apparatus and was located in the floor of the lower mandible. Two types of muscles were found in the tongue: Intrinsic and Extrinsic. The tongue was covered by keratinized epithelium and papillae. The barbs like, keratinized papillae were found in this specimen. The papillae were varying in shape and size. The colour of tongue was black. The lingual nail was found on the ventral surface below the tip of the tongue which was formed by strong and hard keratinized epithelium. Some taste buds were found at the base of the tongue, on the roof and floor of the mouth. Hyoid apparatus was found in form of articulated group of bones and cartilages. The horns of hyoid apparatus were extended caudally from tongue on either side of the larynx. The tongue was thick and fleshy because paraglossum was well developed.

HIGHLIGHTS

- ⦿ The tongue is important to catch/collect, manipulate and swallow the food.
- ⦿ In the Blue and Gold Macaw, the tongue was covered by keratinized epithelium and papillae.

Keywords: Blue gold Macaw, Gross Anatomy, Tongue

Birds have wide variety of shapes and features in tongues. Bird's tongue can be very long, very short, feathered at the tip, have barbs of various sizes, and in some species show specific adaptations for feeding. The tongue is important to catch/collect, manipulate and swallow the food. In some birds' tongues show a remarkable adaptation to a particular feeding method. Parrots have a fleshy tongue with intrinsic muscles to control tongue movement. The hyoid bone supports the tongue, but because of the intrinsic muscles they can move the tongue like mammals. Another unique feature is the wrinkled and folded tongue epithelium which allows the tongue more freedom to be stretched (Al-Zahaby and Elsheikh, 2014).

Many parrots like macaws eat nuts and seeds and have an upper mandible (beak) to provide cracking spaces for seeds of different sizes. The nut is turned by the tongue until the groove or seam is positioned on the cutting edge

of the lower mandible. The tongue holds the seed in place while the bird's jaw splits the seed in half. The tongue also separates out and discards the husk. Small seeds are swallowed whole. The tip is made up of papillae designed to brush up pollen and nectar from flowers. When the tongue is not extended, the papillae lie flat (Emura *et al.*, 2012).

Blue gold Macaw is the largest type of parrot with long tail feathers. The forehead is green, the upper part of the body is in brilliant blue colour and the sides of the neck and body is golden yellow in colour (Fig. 1). These macaws

How to cite this article: Gedam, P.M., Dar, Y., Kumar, A., Chandra, N. and Kumar, P. (2022). Gross Anatomical Features of the Tongue of Blue and Gold Macaw. *J. Anim. Res.*, 12(02): 269-272.

Source of Support: None; **Conflict of Interest:** None



are very docile, gentle, affectionate, inquisitive and intelligent in nature. Peoples like them to rare as a family pet. The numbers of these macaws are decreasing in recent years due to habitat loss and illegal capture for parrot trade (Aizawa *et al.*, 2013). Less information is available about the tongue of Blue gold Macaw. Hence the present study was conducted to evaluate the gross anatomical features of the tongue of Blue gold Macaw.

MATERIALS AND METHODS

For the present study, the specimen of a three and half year old, male Blue gold Macaw, brought for post mortem examination was collected from Department of Veterinary Clinical Complex, College of Veterinary and Animal Sciences, Sardar Vallabhbhai Patel University of Agriculture and Technology, Meerut, Uttar Pradesh, India. The tongue was taken out by dissection method and various gross anatomical features were studied. The biometrical parameters like length, width and thickness were recorded with the help of digital venire caliper and non stretchable thread. The photographs were taken by Nikon stereo microscope (Model No. SMZ1270) with zoom ratio of 12.7x (0.63-8x).

RESULTS AND DISCUSSION

In this specimen, the tongue was found to be a part of the lingual apparatus and was located in the floor of the lower mandible. The lingual apparatus included the cartilaginous and bony skeletal structure that was hyoid apparatus, glands, muscles, nerves, blood vessels, and various connective tissues. Extrinsic connective tissue, including extrinsic muscles were connected the lingual apparatus to the skull. The tongue was covered by keratinized epithelium and papillae. The colour of tongue was black. The tongue was spatula in shape and longitudinal folds covered the dorsum of tongue (Fig. 2&3). The wrinkled and folded tongue epithelium which allows the tongue more freedom to be stretched (Erdogan and Iwasaki, 2013).

The apex was rounded and body was broad. The apex had many grooves and large central groove extended towards the root. The dorsal surface of apex was smooth. The postero-lateral region of the body had a pair of lingual glands. The filliform papillae were found on the longitudinal folds. The circumvallated papillae were

found on the postero-lateral aspect on either side. The conical papillae were observed at the posterior aspect of the lingual body. The fungiform papillae were ill developed. The tongue was connected by frenum linguae with the floor of mouth. The depression was present on the middle of dorsum of tongue. The lingual nail was found on the ventral surface below the tip of the tongue which was formed by strong and hard keratinized epithelium (Fig. 4,6&7). The lingual nail is flexible enough that it can be stretched. In some birds, it may be used as a spoon for lifting grains (Emura *et al.*, 2012; Emura 2016).



Fig. 1: Blue Gold Macaw

Two types of muscles were found in the tongue. Intrinsic tongue muscles were connect the various hyoid apparatus bones and allowed the movement of hyoid bones and tongue. Extrinsic muscles attached the tongue to bones of hyoid apparatus from outside and allowed the tongue to change position (Fig. 2). Birds have only extrinsic muscles but few birds have intrinsic muscles to control the tongue movement (Igwebuike and Anagor, 2013).

The barbs like, keratinized papillae were found in this specimen. The papillae were varying in shape and size for keeping food on the tongue, holding of food and moving food towards the esophagus (Iwasaki *et al.*, 2002). Some caudally directed papillae were also found near the root for to swallow food. V-shaped row of conical papillae pointed caudally and located between the body and root of the

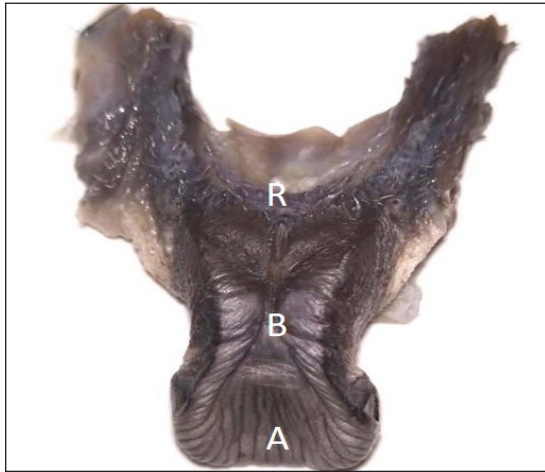


Fig. 2: Photograph showing the Apex (A), body (B) and root (R) of the tongue of macaw (Dorsal View)



Fig. 3: Photograph showing the grooves on the dorsum of the tongue of macaw (Dorsal View)

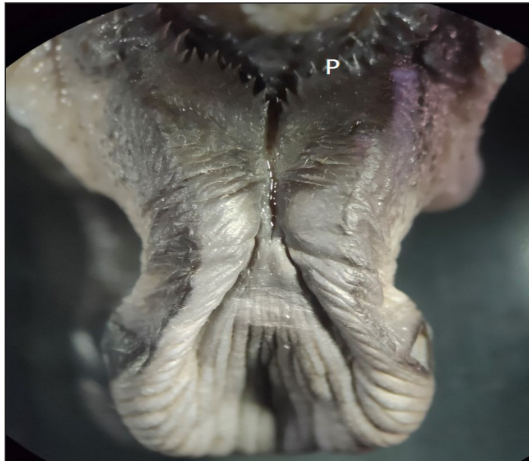

Fig. 4: Photograph showing the conical papillae (P) on the tongue of macaw (Dorsal View)



Fig. 5: Photograph showing the mouth cavity of macaw

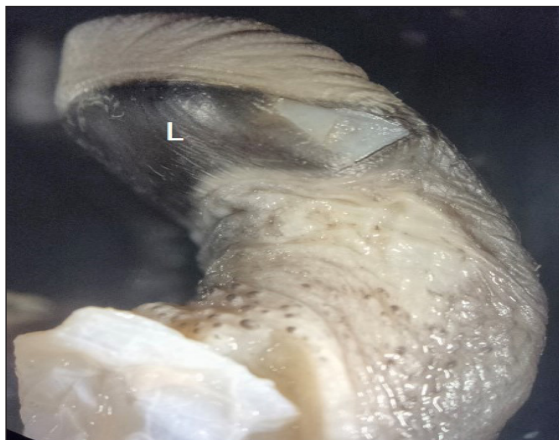

Fig. 6: Photograph showing the Lingual nail (L) of the tongue of macaw (ventral view).



Fig. 7: Photograph showing the Lingual nail of the tongue of macaw (ventral view)

Table 1: Biometrical measurements of the tongue in Blue gold Macaw

Length (mm) of Tongue	Length of hyoid bone from the root (mm)	Width of fold of Tongue(mm)	Width of Tongue (mm)			Thickness of Tongue (mm)		
			Apex	Body	Root	Apex	Body	Root
24.24	19.2	1.32	11.46	9.27	15.17	6.89	8.64	9.41

tongue were also found in this specimen for to facilitates the movement of food towards the esophagus and prevent regurgitation (Fig. 4) (Erdogan *et al.*, 2013).

Hyoid apparatus was found in form of articulated group of bones and cartilages to support and control the movement of tongue, provide attachments for extrinsic muscles, and keep the apparatus in place. The horns of hyoid apparatus were extended caudally from tongue on either side of the larynx. The hyoid horns and their muscles were enclosed in is two layers of connective tissue sheaths with lubricating fluid in between. The tongue was thick and fleshy because paraglossum was well developed (Fig. 2) (Aizawa, *et al.*, 2013) (Nancy, 2014).

CONCLUSION

The tongue was covered by keratinized epithelium and papillae. The barbs like, keratinized papillae were found in this specimen. The lingual nail was found on the ventral surface below the tip of the tongue which was formed by strong and hard keratinized epithelium. The horns of hyoid apparatus were extended caudally from tongue on either side of the larynx. The tongue was thick and fleshy because paraglossum was well developed.

ACKNOWLEDGEMENTS

The authors extend their thanks to Dean COVS, SVPUAT, Meerut for providing the required facilities during the work.

REFERENCES

- Aizawa, J., Tivane, C., Rodrigues, M.N., Wagner, P.G., Campos, D.B., Guerra, R.R. and Miglino, M.A. 2013. Gross anatomical features of the gastrointestinal tract (GIT) of blue and yellow macaws (*Ara ararauna*) - oral cavity and pharynx. *Anat. Histol. Embryol.*, **42**(6): 420-424.
- Aizawa, J., Tivane, C., Rodrigues, M.N., Wagner, P.G., Campos, D.B., Guerra, R.R. and Miglino, M.A. 2013. Gross anatomical features of the gastrointestinal tract (GIT) of blue-and-yellow macaws (*Ara ararauna*) - oesophagus to cloaca. *Anat. Histol. Embryol.*, **42**(6): 432-437.
- Al-Zahaby, S.A. and Elsheikh, E.H. 2014. Ultramorphological and histological studies on the tongue of the common kingfisher in relation to its feeding habit. *The J. Basic & Appl. Zool.*, **67**: 91-9.
- Emura, S., Okumura, T. and Chen, H. 2012. Scanning electron microscopic study on the tongue in the scarlet macaw (*Ara macao*). *Okajimas Folia Anat. Jpn.*, **89**(3): 57-60.
- Emura, S. 2016. Scanning electron microscopic study on the tongues of seven avian species. *Okajimas Folia Anat. Jpn.*, **93**(2): 41-51.
- Erdogan, S. and Iwasaki, S. 2013. Function-related morphological characteristics and specialized structures of the avian tongue. *Annals of Anatomy.* **50823**: 13
- Igwebuike, U.M. and Anagor, T.A. 2013. The morphology of the oropharynx and tongue of the Muscovy duck (*Cairina moschata*). *Vet. Arhiv.*, **83**(6): 685-69.
- Nancy E. Johnston. 2014. The Avian Tongue. *Golden Gate Audubon* 2530 San Pablo Avenue, Suite G Berkeley, California.