



## Protothecosis: A Cause of Chronic Enteropathy/ Large Bowel Diarrhoea in Dogs

Sheetal Dogra<sup>1\*</sup>, Swaran Singh Randhawa<sup>2</sup>, Kuldeep Gupta<sup>3</sup> and Ashwani Kumar<sup>1</sup>

<sup>1</sup>Department of Veterinary Medicine, GADVASU, Ludhiana, INDIA

<sup>2</sup>Department of TVCC, GADVASU, Ludhiana, INDIA

<sup>3</sup>Department of Veterinary Pathology, GADVASU, Ludhiana, INDIA

\*Corresponding author: S Dogra; E-mail: shtl284@gmail.com

Received: 08 June, 2022

Revised: 15 July, 2022

Accepted: 18 July, 2022

### ABSTRACT

Protothecosis is an emerging algal disease which has not been much reported from India. Canine protothecosis typically involves a broadly disseminated infection mainly colitis (with or without hematochezia), a common presenting complaint. Four male dogs out of total 69 cases presented to University Hospital with history of hematochezia for more than 2 months in all cases, high grade fever, inappetance, poor body condition and chronic weight loss. On rectal examination, anal sacculitis ( $n=1$ ) and hematochezia ( $n=4$ ) was seen. Hemogram revealed hemoconcentration, neutrophilic leucocytosis. However, no apparent change seen in biochemistry, fecal examination, radiography and ultrasonography. Acute phase protein and other inflammatory markers were also undertaken to rule out other causes of gastrointestinal signs. Rectal brush cytology was done to rule out rectal mucosal abnormality which revealed large number of prototheca organisms round to oval, having basophilic cytoplasm with an unstained theca within the cytoplasm along with increased no. of normal microflora. Three out of four cases succumbed to disease as of its fatal occurrence. Hypoallergenic diet was given in one case for 2 weeks followed by a course of antibiotic and B-complex. Patient did not respond and then was shifted to *Arsenic album* 30, a homeopathy medicine 4 drops q.i.d for 1 week PO, followed by *Arsenic album* 200 4 drops q.i.d once weekly PO for 4 weeks to which animal responded well. It was concluded that protothecosis carries a grave prognosis in canine patients; however, homeopathy should be tried as an alternative therapy in more number of affected dogs.

### HIGHLIGHTS

- ⦿ Homeopathy can be used as an alternative medicine in Protothecosis.
- ⦿ Protothecosis is also a cause of chronic enteropathy in dogs.
- ⦿ Rectal brush cytology considered as gold standard technique for this disease.

**Keywords:** *Arsenic album* 30, *Arsenic album* 200, Canine, Chronic diarrhoea, Hematochezia, *Prototheca*

Protothecosis in canines is uncommon but increasingly recognised worldwide now. Though, it is an emerging algal disease but has not been much reported from India. In dogs, protothecosis is generally characterized by an insidious onset, a slow progression and a fatal course. The genus *Prototheca* entails species of achlorophyllous, unicellular, saprophytic, aerobic algae closely related to *Chlorella* spp. (Pal *et al.*, 2014). These algae are ubiquitous in the environment and may be isolated from fresh and marine water, soil, mud, tree sap, and sewage (Craig, 2012). *Prototheca* reproduce asexually by internal

cleavage (endospore formation), resulting in the formation of 2 to 20 small endospores within the sporangium, which expand until they are released when the sporangium ruptures (Kano, 2019). Among five species of *Prototheca* including *P. blaschkeae*, *P. stagnora*, *P. ulmea*, *P. wickerhamii*, and *P. zopfii* (Ricchi *et al.*, 2013); *Prototheca wickerhamii* and *Prototheca zopfii*. common in humans,

**How to cite this article:** Dogra, S., Randhawa, S.S., Gupta, K. and Kumar, A. (2022). Protothecosis: A Cause of Chronic Enteropathy/ Large Bowel Diarrhoea in Dogs. *J. Anim. Res.*, 12(04): 535-539.

**Source of Support:** None; **Conflict of Interest:** None



cattle, and dogs (Pressler, 2012 and Vince *et al.*, 2014). It causes severe gastrointestinal (GI) disease and can also affect the skin, the eyes, or the whole body. The infectious agents, *Prototheca zopfii* and *Prototheca wickerhamii*, are commonly found in sewage, animal waste, and tree slime. Animals with defective immune are more susceptible to protothecosis. In the systemic form of protothecosis, the most common clinical sign is intermittent bloody diarrhea or black tarry feces. Weight loss, vomiting, and straining to defecate can also be seen (Pal *et al.*, 2014). Diagnosis is always challenging in these disorders. Diagnostic testing generally include complete blood count (CBC), serum chemistry and electrolytes, urinalysis, faecal examination, faecal culture and ELISA, cytology of rectal scrapings, abdominal radiography and ultrasonography. Nonspecific laboratory findings at early stage mostly mislead the clinicians. The purpose of our prospective study is to establish the etiology and standardize the treatment protocols so that the prognosis in such cases can improve. The approach to these patients is based on severity of the clinical signs of recurrent diarrhoea, weight loss, decreased appetite or activity along with low serum albumin or cobalamin, mesenteric lymphadenopathy and intestinal thickening. Carfora *et al.* (2017) discussed about the dissemination of prototheca infection to nodular and ulcerative dermatitis, ocular and neurological signs, in spite of the fact that the predilection site for this organism is terminal part of colon with clinical signs of gastrointestinal tract.

## MATERIALS AND METHODS

Out of total 69 cases of chronic gastroenteropathies, four male dogs between age group of 4 to 9 years presented with the history of hematochezia from more than 2 months in all cases, high grade fever (3), inappetance (4), poor body condition (3) and chronic weight loss (4), presented in small animal clinics of Teaching Veterinary Hospital of GADVASU were diagnosed for protothecosis. Breeds including German Shepherd (1), Labrador (2) and Dachshund (1) were presented. A complete blood cell count (CBC), serum chemistry, urinalysis, fecal examination, serum ELISA for acute phase proteins (SAA and CRP), cobalamine, folate, bile acids, cortisol, TLI and PLI, were done to rule out enteropathy of small intestinal, hepatic, renal and endocrine origin. Abdominal radiography and ultrasonography was done to rule out any

underlying systemic cause. Rectal brush cytology was done to diagnose any mucosal wall abnormality.

## Animals' ethics

The permission for sampling and other procedures was duly approved by the Institutional Animal Ethics Committee (IAEC) vide memo no. IAEC/2018/1090-1125.

## RESULTS AND DISCUSSION

Four male dogs between age group of 4 to 9 years presented with the history of hematochezia from more than 2 months in all cases, high grade fever (3), inappetance (4), poor body condition (3) and chronic weight loss (4) were diagnosed for protothecosis. Haemorrhagic colitis is the most common complaint in dogs with protothecosis (Carfora *et al.*, 2017; Craig, 2012). The severity of colitis may vary. Diarrhoea is often episodic and is typically observed for several months prior to dissemination of the algae. Poor body condition and fever with normal vitals was found in case report described by Vince *et al.* (2014). A total 5.78 per cent of chronic gastroenteropathies were diagnosed for canine protothecosis. Canine protothecosis is a disseminated disease with an insidious onset, relentless progression and inevitably fatal course. In many patients, colitis is present for many months prior to the onset of signs referable to dissemination (Lane *et al.*, 2012). The majority of affected dogs show progressive weight loss (Craig, 2012); all dogs in the present series had reduced body weight when protothecosis was diagnosed. The reason for this finding is uncertain but possible contributory factors include mild anorexia or vomiting due to abdominal discomfort and increased energy expenditure due to the disease (Lecoindre and Gaschen, 2011). In a detailed study of Masuda *et al.* (2020), taxonomic and clinical features, diagnosis and treatment of protothecosis in dogs and cats were summarised. Another study (Pal *et al.*, 2014) proposed that pathogenesis of protothecosis is still unclear and more investigation is needed for better diagnosis and early detection. The mean rectal temperature, heart rate and respiration rate were  $103.8 \pm 0.54$  °F,  $96.5 \pm 8.02$  beats/min and  $116.5 \pm 16.46$  /min, respectively. The mean value of haemoglobin, TEC, PCV and TLC in the dogs suffering with protothecosis was  $13.80 \pm 1.99$  g/dl,  $5.75 \pm 0.71$ ,  $39.48 \pm 6.26$  and  $20350.00 \pm 3587.17$  respectively. The mean neutrophil, lymphocyte, eosinophil and platelet

count were recorded as  $91.50 \pm 1.50$ ,  $7.50 \pm 1.89$ ,  $0.50 \pm 0.50$  per cent and  $401.50 \pm 146.69 \times 10^3/\mu\text{l}$  respectively (Table 1).

**Table 1:** Hematological parameters in dogs suffering with Protothecosis

Sl. No.	Parameter	Protothecosis (n = 4)	Normal Range
1	Hb (g/dl)	$13.80 \pm 1.99$	11.9-19.0
2	TEC $10^6/\mu\text{l}$	$5.75 \pm 0.71$	4.9-7.8
3	PCV (%)	$39.48 \pm 6.26$	37-54
4	TLC $10^3/\mu\text{l}$	$20350.00 \pm 3857.17$	6000-17100
5	Neutrophil (%)	$91.50 \pm 1.50$	58-85
6	Lymphocyte (%)	$7.50 \pm 1.89$	8-21
7	Eosinophil (%)	$0.50 \pm 0.50$	0-9
8	Platelets $10^3/\mu\text{l}$	$401.50 \pm 146.69$	150-430

Hemogram revealed haemoconcentration, neutrophilic leucocytosis with increased platelets count. Similar findings were present in study (Vince *et al.*, 2014). These changes were characteristic of chronic inflammation or a stress-induced leukogram. On the other hand, Bottero *et al.* (2016) recorded normocytic normochromic, non-regenerative anemia in dogs with protothecosis. Bottero *et al.* (2015) reported hypoalbuminemia, hyponatremia, hyperkalemia in dogs with protothecosis however non significant hyponatremia and hyperkalemia was seen in the present study. In corroboration with study of Vince *et al.* (2014) on protothecosis, the serum biochemistry in present study was also unremarkable (Table 2).

**Table 2:** Biochemical parameters in dogs suffering cases with Protothecosis

Sl. No.	Parameter	Protothecosis (n = 4)	Normal Range
1	SGPT (IU/L)	$66.00 \pm 20.47$	8.2-57
2	ALKP (IU/L)	$126.50 \pm 60.57$	10.6-101
3	Total protein (g/dl)	$5.48 \pm 0.45$	5.5-7.5
4	Albumin (g/dl)	$2.50 \pm 0.41$	2.6-4.0
5	BUN (mg/dl)	$8.50 \pm 0.65$	8.8- 25.9
6	Creatinine (mg/dl)	$0.93 \pm 0.11$	0.5-1.6
7	Sodium (mg/dl)	$134.50 \pm 12.90$	140-154
8	Potassium (mg/dl)	$4.68 \pm 0.34$	3.6-3.8
9	Calcium (mg/dl)	$8.55 \pm 1.16$	8.7-11.8
10	Cholesterol (mg/dl)	$177.75 \pm 29.25$	116-254

No remarkable changes were seen in SAA, CRP, Bile Acid, Cortisol, Folic Acid, Cobalamin, TLI and PLI (Table 3). Less work has been done on these parameters. Studies in the canine patient have been more limited. Bottero *et al.* (2016) in his study recorded normal values of TLI, Folate and cobalamine in dogs suffering from protothecosis.

**Table 3:** Acute phase proteins and other markers in dogs suffering from Protothecosis

Sl. No.	Parameter	Protothecosis (n = 4)	Normal Range
1	SAA ( $\mu\text{g/ml}$ or $\text{mg/L}$ )	$0.49 \pm 0.38$	1.06 -56.4
2	CRP ( $\mu\text{g/ml}$ or $\text{mg/L}$ )	$5.43 \pm 0.47$	0.07-24.7
3	Bile Acid ( $\text{mmol/L}$ )	$3.92 \pm 0.45$	0.6- 24.2
4	Cortisol ( $\mu\text{g/dL}$ )	$100.59 \pm 9.88$	1-18.58
5	Folic Acid ( $\text{ng/ml}$ or $\mu\text{g/L}$ )	$1.04 \pm 0.46$	7.7- 24.4
6	Cobalamin ( $\text{ng/ml}$ )	$1.51 \pm 1.05$	0.25- 0.908
7	TLI ( $\mu\text{g/L}$ )	$36.08 \pm 10.08$	5-35
8	PLI ( $\mu\text{g/L}$ )	$61.97 \pm 2.52$	0-200

#### Fecal examination

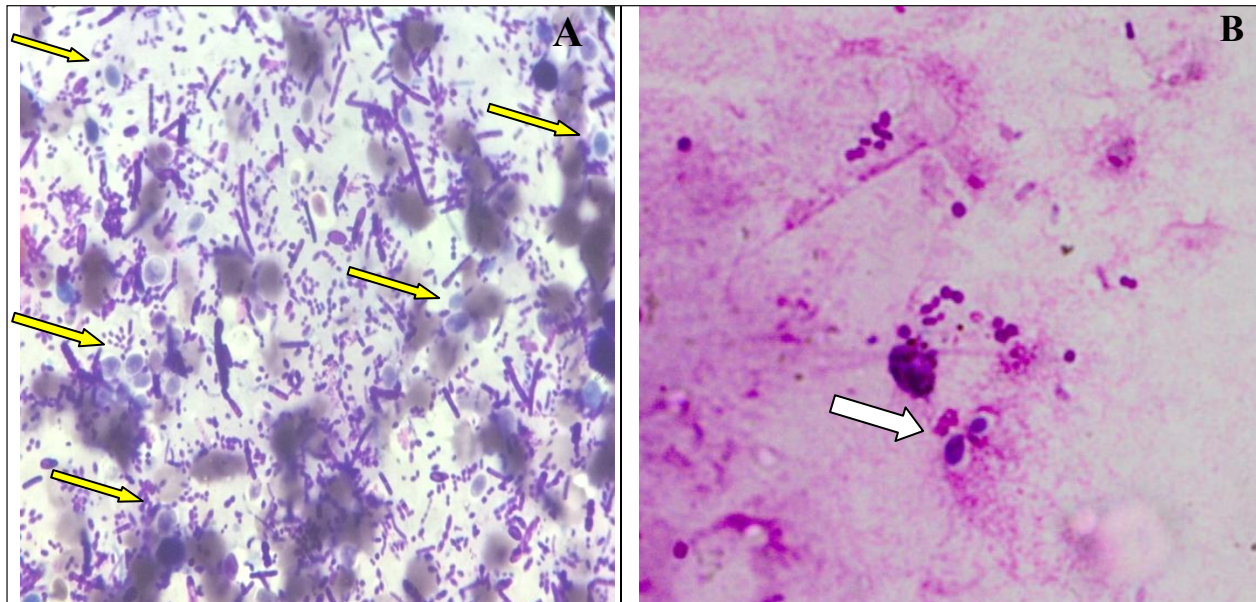
Fecal sample was negative for ova/cyst in all the four cases of protothecosis. All the studies previously reported, did not use the fecal examination for diagnosis of protothecosis (Carfora *et al.*, 2017).

#### Diagnostic imaging

Radiography and ultrasonography were not of diagnostic value in case of protothecosis except loss of layering in colon in one case. It is complicated by the numerous other causes of chronic diarrhoea and therefore early detection of this pathogen is required as in the present study one case which was initially diagnosed for protothecosis was later on confirmed for rectal adenocarcinoma on successive rectal brush cytology. It is said that if protothecosis is not diagnosed at proper time, it can lead to broad systemic dissemination and can become more fatal (Vince *et al.*, 2014).

#### Rectal brush cytology

Pal *et al.* (2014) and Bottero *et al.* (2016) in their findings indicated that *Prototheca* spp. should be considered as



**Fig. 1:** *Prototheca* in rectal smear cytology. **(A)** Large number of *Prototheca* (yellow arrow) with blue cytoplasm with transparent wall (*Leishman stain* × 100 X). **(B)** *Prototheca* (two in number; white arrow) in rectal smear (*Leishman stain* × 100 X)

a part of differential diagnoses for chronic large bowel diarrhoea in dogs.

Rectal brush cytology was helpful in diagnosing canine protothecosis in all four dogs which is considered as gold standard technique for this disease. Another studies (Dunham and Guptill, 2011; Vince *et al.*, 2014) observed that the rectal scrappings were ultimate diagnostic technique for diagnosis of protothecosis. Large number of prototheca organisms (yellow arrows) round to oval, having a granular, basophilic cytoplasm with clear cell wall along with increased number of microflora (Fig. 1: A and B). Vince *et al.* (2014) cultured fecal samples from the affected dogs and identified *P. zopfii* as the cause of protothecosis in these dogs. Bottero *et al.* (2016) did PCR on tissue biopsy samples from colon in all the four affected dogs and identified algal DNA in all the four cases where as (Dunham and Guptill, 2011) demonstrated organisms in colon biopsy samples. However, Pal *et al.* (2014); Craig, (2012) and Lane *et al.* (2012) worked on systemic protothecosis and did microscopic examination of urine, CSF, rectal scrapings and biopsies from eyes, colon, skin and lymph nodes for diagnosis of protothecosis.

### Treatment

Protothecosis is difficult to treat. Successful treatment

is rare (Manino *et al.*, 2014 and Pal *et al.*, 2014). Three out of four cases succumbed to disease as of its fatal outcome. Hypoallergenic diet was given in one case for 2 weeks followed by a course of antibiotic and B-complex. Slight improvement was seen in the consistency of feces and hematochezia. The patient was shifted to *Arsenic album* 30, a homeopathy medicine 4 drops q.i.d for 1 week PO, followed by *Arsenic album* 200 4 drops q.i.d once weekly PO to which animal responded well and no blood was seen in feces after the treatment. Dog's appetite also improved with no signs of nausea and vomiting thereafter. Alternatively, homeopathy was tried in one case of protothecosis in our study. The cornerstone principle of homeopathy is Similia Similibus Curentur, "Let likes cure likes" that means any drug which cures a condition produces similar signs if given in a healthy patient. Secondly, initially drug should be used in low potency frequently and later on the patient should be shifted on high potency less frequently.

Protothecosis carries a grave prognosis in the canine patient Poor prognosis associated with protothecosis could be related to the late stage of diagnosis in the progression of disease and that early detection of infection might permit earlier and more effective treatment before extensive dissemination (Vince *et al.*, 2014; Carfora *et*



al., 2017). There are currently no treatment guidelines for canine protothecosis available. In vitro studies have shown that *Prototheca* spp. are sensitive to amphotericin B, azoles and a wide range of antibacterial agents (Manino *et al.*, 2014) but have not shown convincing efficacy in dogs (Vince *et al.*, 2014). In all cases described in the present study, itraconazole was used, alone or together with enrofloxacin. Treatment induced only partial and temporary remission of clinical signs in two dogs. As described in the literature (Pressler, 2012) protothecosis is a progressive disease with death occurring in all dogs between one and twelve months after the initial diagnosis. Colonic histology samples and cytological rectal scrapings in dogs with chronic gastrointestinal signs should be done to identify infection with *Prototheca* spp.

## CONCLUSION

In conclusion, in the present study three out of four male dogs were diagnosed for protothecosis. Rectal brush cytology was diagnostic in all the cases. Prognosis is fatal. Our findings indicate that infection with *Prototheca* spp. could be a differential diagnoses for chronic large bowel diarrhoea in dogs. Rectal brush cytology which is considered as gold standard technique for this disease. In the early phase of disease, animal show only limited and unspecific clinical findings and only cytological rectal scrapings in dogs with severe colitis may be helpful to identify infection with *Prototheca* spp.

## ACKNOWLEDGEMENTS

The authors are thankful to Guru Angad Dev Veterinary and Animal Sciences University (GADVASU), Ludhiana for providing all type of facilities to carry out the study. The funding for this study was provided by DBT – GADVASU Canine Research Centre and Networks.

## REFERENCES

- Bottero, E., Mercuriali, E., Abramo, F., Dedola, B., Martella, V. and Zini, E. 2016. Fatal protothecosis in four dogs with large bowel disease in Italy. *Vet. Med. Austria.*, **103**: 1–53.
- Carfora, V., Noris, G., Caprioli, A., Iurescia, M., Stravino, F. and Franco, A. 2017. Evidence of a *Prototheca zopfii* genotype 2 disseminated infection in a dog with cutaneous lesions. *Mycopathologia*, **182**(5): 603-608.
- Craig, E.G. 2012. Infectious Diseases of the Dog and Cat, 4<sup>th</sup> ed. Saunders, Elsevier Inc., pp. 696-701.
- Kano, R. 2019. Emergence of fungal-like organisms: Prototheca. *Mycopathologia*. <https://doi.org/10.1007/s11046-019-00365-4>.
- Lane, L.V., Meinkoth, J.H., Brunker, J., Smith, S.K., Snider, T.A., Thomas, J. and Love, B.C. 2012. Disseminated protothecosis diagnosed by evaluation of CSF in a dog. *Vet. Clin. Pathol.*, **41**(1): 147-152.
- Manino, P.M., Oliveira, F., Ficken, M., Swinford, A. and Burney, D. 2014. Disseminated protothecosis associated with diskospondylitis in a dog. *J. Am. Anim. Hosp. Assoc.*, **50**: 429–35.
- Masuda, M., Jagielski, T., Danesi, P., Falcaro, C., Bertola, M., Krockenberger, M., Malik, R. and Kano, R. 2021. Protothecosis in Dogs and Cats—New Research Directions. *Mycopathologia.*, **186**(1): 143-152.
- Pal, M., Abraha, A., Rahman, M.T. and Dave, P. 2014. Protothecosis: An Emerging Algal Disease of Humans and Animals. *Int. J. Lifesc. Bt. & Pharm. Res.*, **3**(4): 1-13.
- Pressler, B.M. 2012. Ptothecosis. *In*: Green CE, editor. Infectious diseases of dog and cat. 4<sup>th</sup> ed. St. Louis: Saunders Elsevier, pp. 696–701.
- Ricchi, M., De, Cicco, C., Buzzini, P., Cammi, G., Arrigoni, N., Cammi, M. and Garbarino, C. 2013. First outbreak of bovine mastitis caused by *Prototheca blaschkeae*. *Vet. Microbial.*, **162**(2-4): 997-999.
- Vince, A.R., Pinard, C., Ogilvie, A.T., Tan, E.O. and Abrams-Ogg, A.C. 2014. Case Report: Protothecosis in a dog. *Can. Vet. J.*, **55**(10): 950.

