

Chemopreventive Potential of Methanolic Extract of *Leucas aspera* Against N-Nitrosodiethyl Amine (NDEA) Induced Hepatotoxicity in Rats

*Latha Bhaskara Kurup and Mukalel Sankunni Latha

Biochemistry and Pharmacognosy Research Laboratory, School of Biosciences, Mahatma Gandhi University, P.D. Hills P. O, Kottayam, Kerala, India, 686 560

*Email: lathavijay01@gmail.com

Abstract

N-nitrosodiethylamine (NDEA), a chemical carcinogen present in many environmental factors. It induces oxidative stress and cellular injury due to enhanced generation of reactive oxygen species. Free radical scavengers protect the membranes from NDEA-induced damage. Objectives: The present study was designed to evaluate the chemopreventive effect of methanolic extract of *Leucas aspera* (MELA) against NDEA induced liver toxicity in male wistar rats. Methods: NDEA was administered for 20 weeks. Daily doses of (MELA) at doses 100 and 200mg and standard drug *Silymarin* at a dose of 50 mg/kg bodyweight were administered one week before the onset of NDEA intoxication and continued for 20 weeks. Results: Rats intoxicated with NDEA had elevated levels of serum alpha-fetoprotein (AFP), carcinoembryonic antigen (CEA), aspartate amino transferase (AST), alanine aminotransferase (ALT), lactate dehydrogenase (LDH), γ -glutamyl transpeptidase (γ -GGT), bilirubin, tissue lipid peroxides (TBARS & CD) and decreased levels of serum total protein, albumin & uric acid levels whereas MELA and *Silymarin* treatment showed decreased levels of AFP, CEA, uric acid, hepatic marker enzymes, lipid peroxide levels, protein and albumin to near normal. Histopathological observation also substantiated NEDA-induced hepatotoxicity and the effect was significantly ($p < 0.05$) reduced by *Leucas aspera* extract and *Silymarin* treatment. Conclusions: The study reveals that (MELA) at a dose of 200mg/kg effectively reversed the hepatotoxicity induced by N-nitrosodiethylamine in rats. Histopathological studies also confirmed that MELA reduced tumor incidence and reversed the damaged hepatocytes to near normal.

Keywords: Nitrosodiethyl amine, *Leucas aspera*, Chemoprevention, Histopathology

Introduction

Hepatocarcinogenesis is a multistep process. N-nitrosodiethyl amine (NDEA), a chemical carcinogen widely used to initiate hepatocarcinogenesis in rats (Jose *et al.*, 1988; Thirunavukkarasu and Sakhisekaren,

2001). Food stuffs such as milk and meat products, salted fish, alcoholic beverages and a few varieties of vegetables are the principal sources of nitroso compounds. NDEA has been suggested to cause oxidative stress and cellular injury due to the enhanced formation of free radicals. NDEA has



been shown to be metabolized to its active ethyl radical metabolite, and reactive products interact with DNA causing mutation which leads to carcinogenesis.

In spite of tremendous advances in modern medicine, there are not many effective drugs available that stimulate liver function, offer protection to the liver from damage or help to regenerate hepatic cells (Chattopadhyay, 2003). Antioxidant agents of natural origin have attracted special interest because they can protect human body from free radicals. Medicinal properties of plants have also been investigated due to their potent pharmacological activities, low toxicity and economic viability, when compared with synthetic drugs (Vadlapudi and Naidu, 2010).

Several herbal drugs have been evaluated for its potential as liver protectant against N-nitrosodiethyl amine induced hepatotoxicity in rats (Shajahan *et al.* (2005); Sultana *et al.* (2005). Experimental studies have demonstrated that *L. aspera* methanolic extract could protect the liver from carbontetra chloride induced acute toxicity in rats (Shirish.S., 2010; Radhika *et al.*, 2011; Latha.B & M.S Latha., 2013). The methanolic extract of *Leucas aspera* was found to contain alkaloids, steroids, tannins, flavonoids, glycosides and phenols on preliminary phytochemical analysis. In spite of its various medicinal uses, no systematic studies in the literature regarding antihepatocarcinogenic potential of *L. aspera* in NDEA induced liver toxicity in male wistar rats.

Objective of the study was to evaluate the chemopreventive effect of methanolic extract of *Leucas aspera* (MELA) at doses 100 and 200mg and standard hepatoprotective drug *Silymarin* at a dose of 50mg/kg bodyweight against NDEA induced liver toxicity in adult Wistar rats.

Materials and methods

Chemicals and reagents

NDEA, Silymarin, Thiobarbituric acid (TBA) were purchased from Sigma Chemical co., St. Louis, MO, USA. Assay kits for AFP, CEA, AST, ALT, LDH, ALP, total protein, bilirubin and uric acid from Agabbe surgicals Ltd. India. All other materials and chemicals used in the study were of analytical grade and purchased from reliable firms and Institutes (SRL, MERCK, RANBAXY, HIMEDIA).

Preparation of the plant extract

The whole plant of *L. aspera* was collected from Kottayam, Kerala and authenticated. A voucher specimen (SBSBRL-

04) is maintained in the Institute. The plant as a whole was taken, washed thoroughly, shade-dried and powdered. A 100g of dried powder of the plant was soxhlet extracted with 500ml of methanol for 24h. The solvent was concentrated in a rotary evaporator to yield 4.6% dried extract and stored in air tight containers.

Animals

Male wistar rats (150-200g), provided from the animal house were used in this study. The rats were housed in clean polypropylene cages (6 rats) at ambient temperature and humidity with a 12 h day-night cycle and fed with commercial rat feed and water ad libitum. Animal studies were followed according to Institute Animal Ethics committee regulations approved by CPCSEA and conducted humanely.

Experimental studies

Preventive effect of the extract

Thirty six rats were divided into 6 groups, group I was normal control, group II was NDEA control, groups III & IV were standard drug Silymarin (50mg/kg) and *L. aspera* methanolic extract at a dose of 200mg and group V & VI were MELA at doses of 100 and 200mg/kg b.wt respectively. Hepatotoxicity induced by N-nitrosodiethyl amine (NDEA) administration was studied for a period of 20 weeks. In groups II, III, V & VI liver tumors were induced by oral administration of 0.01% NDEA in water 5 days/week for 20 weeks (Jeena *et al.*, 1999). Daily doses of *L. aspera* extract (200mg/kg) suspended in 5% Tween 80 orally treatment were started in group IV animals one week before the onset of NDEA administration and continued up to 20 weeks. The rats were sacrificed 48 h after the last dose of NDEA administration.

Animals were sacrificed and blood samples were collected. The liver was removed rapidly and cut into separate portions for antioxidant enzymes, lipid peroxide estimation and histopathological studies. AST, ALT, γ -GGT, Bilirubin, Total protein, Albumin and Uric acid in serum were assayed by using Agabbe diagnostic kits by kinetic method using semi autoanalyzer (RMS, India). AFP and CEA were measured in blood serum by Chemiluminescent immunoassay (AccuLite CLIA Microwells, Monobind Inc. USA. Chemiluminescence system).

500mg liver tissue was homogenized with 5ml, 0.025M Tris-HCl buffer. Liver homogenate were centrifuged at 2500rpm for 15 min and the supernatant was used for the

assays. Lipid peroxidation levels in liver homogenate were measured in terms of thiobarbituric acid reactive substances (TBARS) by Nichau's and Samuelson, 1966 method and conjugated dienes (CD) by Recknagel, 1966. An extra sample of liver was excised and fixed in 10% formalin solution for histopathological analysis (Galigher *et al.*, 1976).

Histopathological studies

Liver specimens were preserved in 10% neutral buffered formalin and dehydrated in a graded alcohol series. Following xylene treatment, the specimens were then embedded in paraffin blocks and cut into 5 μm thick sections. Sections were stained with hematoxylin and eosin (H&E).

Statistical analysis

Results were expressed as Mean \pm S.D and all statistical comparisons were made by means of one way ANOVA test followed by Tukey post hoc analysis and p-values less than or equal to 0.05 were considered significant.

Results

Morphology of liver

Fig 1(A to F) shows morphology of liver in toxic control and extract treated rats.


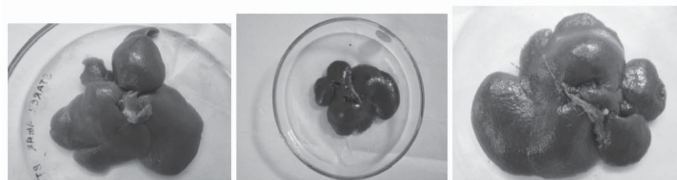


Figure 1: (A to F): Morphology of liver in Experimental groups (A) Normal (B) NDEA control (C) NDEA + MELA 200mg



(D) NDEA + MELA 100mg (E) MELA(200mg)alone (F) Silymarin(50mg)+NDEA

Analysis of alpha-fetoprotein (AFP) and carcinoembryonic antigen (CEA)

Figure 2&3 shows the effect of NDEA on AFP and CEA in the control and experimental groups of animals respectively. The significant increase in the levels of AFP and CEA in the serum was observed in NDEA alone groups as compared to normal and Significant decrease of the level of these tumor markers in the MELA and Silymarin treated groups.

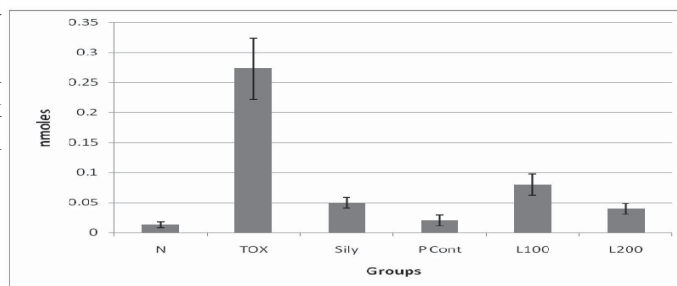


Figure 2: Alphafetoprotein levels

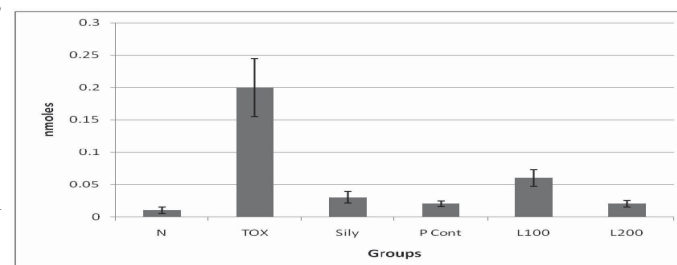


Figure 3: Levels of Carcinoembryonic antigen

Effect of MELA on serum enzymes, lipid peroxides, bilirubin, total protein, albumin and uric acid

Changes in the activities of serum enzymes AST, ALT, LDH, γ -GGT, lipid peroxides, bilirubin, total protein, albumin and uric acid in the serum of NDEA-induced liver toxicity in rats were summarized in Table 1&2. The level of ALT, AST, LDH, γ -GGT & bilirubin in serum and liver lipid peroxides were increased in NDEA control group as compared to the normal group. After administration of MELA at different doses (100 and 200 mg/kg.b.w.) and Silymarin at a dose of 50mg/kg.b.w. to NDEA-induced rats levels of above mentioned parameters were reduced in comparison to the NDEA control group. MELA (200mg/kg) alone treated rats were comparable to normal control group.

The uric acid, Total protein and Albumin levels in serum in NDEA control group decreases in comparison with the

Table 1: Levels of serum marker enzymes

Treatment groups	AST(IU/L)	ALT(IU/L)	LDH(IU/L)	̑GGT(IU/L)
Normal	157.3 ± 2.3	57.5 ± 2.2	159.5± 1.5	8.8 ± 0.6
NDEA control	286.7±13.7 [#]	147.3± 5.0 [#]	316.0±11.7 [#]	28.5± 3.4 [#]
Silymarin(50mg/kg)+NDEA	181.3± 5.8 [*]	63.3± 1.3 [*]	192.83±2.0 [*]	11.5± 0.3 [*]
L.asperaextractalone(200mg/kg)	154.6± 0.9 ^{NS}	56± 1.1 ^{NS}	166.1±2.3 ^{NS}	9.0± 0.3 ^{NS}
L.asperaextract(200mg/kg)+NDEA	180.7 ±2.9 [*]	66.1± 0.9 [*]	187.20± 3.7 [*]	10.3± 0.4 [*]
L.asperaextract(100mg/kg)+NDEA	197.7 ± 2.3 [*]	71.6± 1.9 [*]	202.33 ± 6.4 [*]	12.2± 0.2 [*]

Values are mean ± S.D., n = 6

[#]p≤ 0.05 Vs normal control; ^{*}p≤ 0.05 Vs NDEA control; NS- Nonsignificant compared to group 1

Table 2: Levels of Bilirubin, Totalprotein, Albumin and Uricacid in the serum and lipid peroxides

Treatment groups	Bilirubin (mg/dL)	Totalprotein (g/dL)	Albumin (g/dL)	Uricacid (mg/dL)	TBARS (n moles)	CD(n moles)
Normal	1.01±0.01	7.15± 0.5	3.4 ± 0.4	2.8±0.12	1.97± 2.31	60.05± 3.95
NDEA control	2.25±0.2 [#]	4.7 ± 0.3 [#]	2.4±0.21 [#]	1.46±0.5 [#]	9.44±5.84 [#]	162.9±11.12 [#]
Silymarin(50mg/kg)+NDEA	1.19±0.05 [*]	6.90± 0.5 [*]	3.3 ± 0.5 [*]	2.65±0.1 [*]	3.5 ± 2.95 [*]	82.84 ± 4.58 [*]
L.asperaextract alone(200mg/kg)	0.41±0.04 ^{NS}	7.1± 0.3 ^{NS}	3.5±0.4 ^{NS}	2.7±0.1 ^{NS}	3.1±1.32 ^{NS}	68.58± .59 ^{NS}
L.aspera extract(100mg/k)+NDEA	1.29±0.03 [*]	6.80 ± 0.4 [*]	3.1 ± 0.3 [*]	2.52±0.2 [*]	6.14± 4.6 [*]	140.0 ± 8.75 [*]
L.aspera extract(200mg/k)+NDEA	1.14±0.03 [*]	6.98 ± 0.3 [*]	3.31±0.1 [*]	2.71±0.2 [*]	3.94±2.26 [*]	74.27± 3.88 [*]

Values are mean ± S.D., n = 6

[#]p≤ 0.05 Vs normal control; ^{*}p≤ 0.05 Vs NDEA control. TBARS: n moles of MDA/gm tissue; CD millimoles /100gm tissue; NS- Nonsignificant compared to group 1

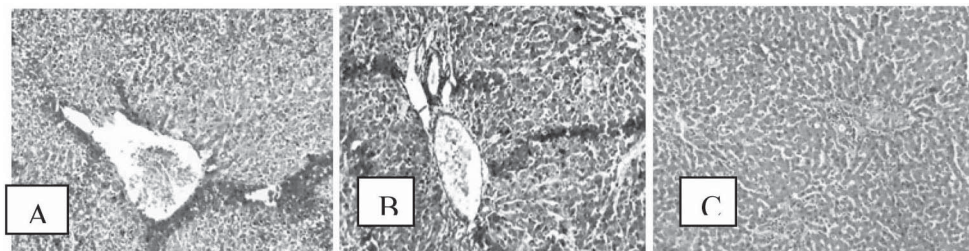
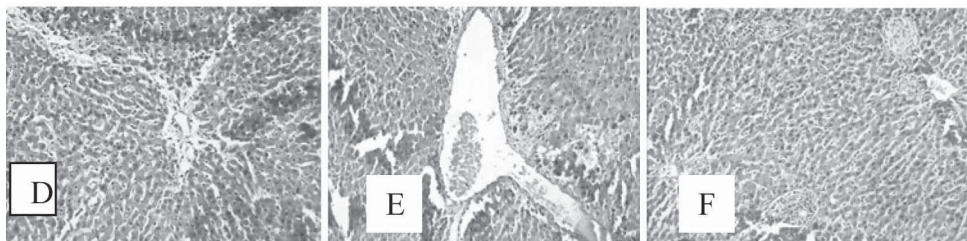


Figure 4: (A to F) : Histopathological studies on experimental groups



A) Normal B) NDEA toxic C) Silymarin D) plant control E) L100 F) L200

normal group. Treatment with MELA at 100 and 200 mg and Silymarin at a dose of 50mg/kg.b.w. increases the levels when compared to that of NDEA control. Treatment with MELA and Silymarin at a dose of 50mg/kg.b.w. increases the levels of total protein by 85.71%, 93.06%, 89.80% & albumin by 82%, 91%, 90% respectively when compared to that of NDEA control. MELA alone (200mg/kg) treated rats were comparable to normal control group. The protein and albumin level in NDEA control group decreases in comparison with the normal group. Treatment with MELA at doses of 100 and 200 mg/kg. b.w. increases the levels of protein and albumin.

Histopathological results

Histological examination of the liver showed normal architecture in the normal control and MELA alone treated control groups (Fig 2A and 2D); Silymarin treated (Fig 2C) and MELA treated rats (Fig 2E & 2F). However, cellular damage with malignancy was obvious in the NDEA treated liver. The liver showed loss of architecture, nodular arrangement (pseudolobule formation) surrounded by lymphocyte infiltrate (Fig 2B). In contrast, NDEA with Silymarin and MELA preventive treatment showed near normal hepatocytes with lymphocyte infiltration formed around the central vein without disruption of the liver architecture (Fig 2c, 2E & 2F).

Discussion

The essential nature of any cancer in humans or in animals continues to challenge many scientists and practitioners interested in the biology, prevention and therapy of the disease. Therefore, the search for new chemo preventive and antitumor agents that are more effective and less toxic than existing agents has kindled great interest in phytochemicals. Phytochemicals possess good antioxidant activities and has been reported to exhibit multiple biological effects including anti-inflammatory, antitumor activities. The presence of sterols, flavonoids and alkaloids in the extract of MELA act as primary antioxidants or free radical scavengers.

Liver diseases remain as one of the serious health problems. Liver is the commonest site affected during the toxic manifestation of many drugs. N-nitrosodiethylamine (NDEA) is a major environmental hepatocarcinogen. Since liver is the main site of NDEA metabolism, the production of ROS in the liver may be responsible for its carcinogenic effects (Bansal *et al.*, 2005). NDEA is well known to generate free radicals, disturbing the antioxidant status and

ultimately leading to oxidative stress and carcinogenesis (Gey, 1993).

Silymarin, isolated from *Silybum marianum* has shown to have significant anticancer effect on several cancers both invitro and invivo. The effect of Silymarin on N-nitrosodiethylamine induced hepatocarcinogenesis in rats was studied by G. Ramakrishnan *et al.*, 2007. The anti angiogenic effect of *Lygodium flexuosum* extract was evaluated in wistar rats intoxicated with N-nitrosodiethylamine (NDEA) in preventive and curative models (P.J. Wills *et al.*, 2006). *L. flexuosum* extract at a dose of 200mg/kg effectively reversed the hepatotoxicity induced by NDEA in both experimental models.

AST and ALT activities in blood serum are generally accepted as an index of liver damage. An elevated serum aminotransferase activities were observed in animals treated with NDEA. MELA at two doses and Silymarin caused a significant decrease in ALT and AST levels in NDEA treated rats. The elevated levels of LDH may be due to its overproduction by tumor cells. Proliferating malignant cells exhibit very high rates of glycolysis, which subsequently lead to elevated LDH activity. The results of the present study are in agreement with literature data and show elevated levels of LDH in blood serum of NDEA administered rats, and this elevation was attenuated in MELA and Silymarin treated rats. GGT is one of the important indicators of liver injury, and their elevation reveals cholestasis and bile duct necrosis. This enzyme is induced mainly in the perportal areas of the liver by a wide range of chemopreventive agents.

Elevation of serum AFP levels has been reported in several diseases including HCC* (Abeleb G I, 1986). AFP along with CEA is most extensively used in the diagnosis of HCC. In our study also there was an increased level of AFP and CEA in the carcinogen administered rats confirming the presence of HCC. MELA at 100 and 200mg doses and Silymarin at 50mg dose significantly reduced the elevation of AFP and CEA levels. The reduced level of uric acid in hepatocarcinogenic conditions may be due to the increased utilization of uric acid against increased production of the free radicals, which is a characteristic feature of cancer condition. The altered uric acid level to near normal in MELA and Silymarin treated rats could be due to strong antioxidant property of MELA and Silymarin, which contributes to its anti carcinogenic potency.

Free radicals react with lipids causing per oxidation, resulting in the release of products such as



malondialdehyde, hydrogen peroxide, and hydroxyl radicals. Antioxidant and curative effect of *Leucas aspera* methanolic extract against carbontetra chloride induced acute liver injury in rats was studied by B.Latha and M.S.Latha; 2013.

An increase in lipid peroxides indicates serious damage to cell membranes, inhibition of several important enzymes, reduced cellular function, and cell death (Pomplla *et al.*, 1991). Lipid per oxidation plays an important role in carcinogenesis (Banakar *et al.*, 2004) and may lead to the formation of several toxic products, such as malondialdehyde (MDA) and 4-hydroxynonenal. These products can attack cellular targets including DNA, thereby inducing mutagenicity and carcinogenicity (de Zwart *et al.*, 1999). Free radicals, mostly ROS, cause cellular injury, the consequences of which are often exhibited and measured as lipid per oxidation (Spiteller, 1996).

Our data showed that NDEA administration profoundly increased the level of lipid per oxidation. The current study showed a significant decrease in TBARS and CD activity in rats treated with MELA and Silymarin. Tumour cells have been reported to sequester essential antioxidants from the circulation, in order to meet the demands of the growing tumour (Buzby *et al.*, 1980).

A novel flavonoid (Leucasin 5,7-dihydroxy-2-14-methoxy-15-propyl phenyl 4H- chromen-4-one) was isolated from *Leucas aspera* leaves by Meghashri *et al.*, 2010. Alpha-farnesene and menthol were isolated from the leaf volatiles, amyl propionate and isoamyl propionate were isolated from the flower volatiles of *L.aspera*. Studies on the methanolic extracts of *L.aspera* have indicated the presence of macelignan, nectandrin B, machilin chrysoerol, acacetin and apigenin (Sadhu *et al.*, 2003). HPLC studies have indicated the presence of luteolin in significant quantities and kaempferol, quercetin and apigenin in considerable amounts in hydroalcoholic extract of aerial parts of *L. aspera* (willd) (Kripa *et al.*, 2010). LCMS-analysis in our study revealed the presence of Beta-sitosterol, Chrysoeriol, Dotriacontanol, Leucasperone B and Leucasperone A in the methanolic extract of *L.aspera*.

Conclusion

It may be inferred from the present study that the hepatoprotective activities of the methanolic extract of *Leucas aspera* in NDEA-induced toxicity may involve its oxidative free radical scavenging activities by alleviating lipid per oxidation through scavenging of free radicals, or

by enhancing the activity of antioxidants. The mechanism of action is yet to be investigated but may be due to the antioxidant effects of sterols, flavonoids and alkaloids present in the plant. This plant can be used safely for longer duration as a cheap source of active therapeutics for alleviation of commonly occurring ailments by the poor and under privileged people of India. Also, the results from this study have confirmed the rationale for the folkloric use of the plant in the treatment of cancer related hepatic disorders.

Acknowledgments

Financial assistance from Mahatma Gndhi University as Junior Research Fellowship to Latha.B is thankfully acknowledged. Authors are thankful to Mr. Ansil P.N, Mr.Jayesh Kuriakose, Mr. Binil Eldhose, Reseach scholars, SBS, M..G University, Kottayam for their timely help in this work.

References

- Latha, B. and Latha, M. S. 2013. Antioxidant and curative effect of *Leucas aspera* methanolic extract against Carbontetra chloride induced acute liver injury in rats. *IJPPS*, **5**: 374-378.
- Radhika, J. and Brinda, P. 2011. Free radical scavenging activity of *Leucas aspera*, wild against CCl_4 induced hepatotoxicity in albino rats. *IJPT*, **3**:1456-146
- Megharshi, S., Vijay Kumar, H. and Gopal, S. 2010. Antioxidant properties of a novel flavonoid from leaves of *Leucas aspera*. *Food chemistry*, **122**: 105-110.
- Shrish. S. Pingale. 2010. Hepatoprotection by *Leucas aspera*: *Der pharma chemica*, **2**(5): 458-62
- Kripa, K.G., Chamundeswari, D., Thanka, J. and Uma Maheswara Reddy, C. 2010. Effect of hydroalcoholic extract of aerial parts of *Leucas aspera* (wild). Link on inflammatory markers in complete Freund's adjuvant induced arthritic rats. *International Journal of Green Pharmacy*,
- Ramakrishnan, G., Augustine, T.A., Jayan, S., Vinodhkumar, S.R. and Devaki, T. 2007; 29. Effect of silymarin on N-nitrosodithyl amine induced hepatocarcinogenesis in rats. *Exp oncol*, **1**: 39-44
- Wills, P.J., Suresh, V., Arun, M. and Asha, V.V. 2006. Antiangiogenic effect of *Lygodium flexiosum* against N-nitro sodiethyl amine-induced hepatotoxicity in rats. *Chemico-Biological interactions*, **164**: 25-38
- Bansal, A.K., Bansal, M., Soni, G. and Bhatnagar, D. 2005. Protective role of Vitamin E pre treatment on N-nitrosodiethylamine induced oxidative stress in rat liver. *Chemico-Biological Interactions*, **156**(2-3): 101
- Sultana, S., Ahnmed, S., Jahangir, T. and Sharma, S. 2005. Inhibitory effect of celery seeds extract on chemically induced hepato carcinogenesis: modulation of cell proliferation, metabolism and a altered hepatic foci development, *cancer Lett.* **221** : 11-20.



- Shajahan, M., Vani, G. and Shymaladevi, C.S. 2005. Effect of solanum, trilobatum on the antioxidant status during diethyl nitrosamine induced and phenobarbital promoted hepatocarcinogenesis in rat, *chem. Biol. Interact*, **156**: 113-123.
- Banakar, M.C., Paramasivan, S.K., Chattopadhyay, M.B., Datta, S., Chakraborty, P., Chatterjee, M., Kannan, K. and Thygarajan, E. 2004. α , 25-dihydroxyvitamin D₃ prevents DNA damage and restores antioxidant enzymes in rat hepatocarcinogenesis induced by diethylnitrosamine and promoted by phenobarbital. *World Journal of Gastroenterology*, **10**(9): 1268-75.
- Sadhu, S. K., Okuyama, E., Fujimoto, H. and Ishibashi, M. 2003. Separation of *Leucas aspera*, a medicinal plant of Bangladesh, guided by prostaglandin inhibitory and antioxidant activities-chemical pharmaceutical bulletin, **5**:595-598.
- Chattopadhyay, R.R. 2003. Possible mechanism of hepatoprotective activity of *Azadirachta indica* leaf extract Part- II. *Journal of Ethnopharmacology*, **89**: 217-219.
- Thirunavukkarasu, S. and Sakthisekaran, D. 2001. Effect of selenium on N- nitrosodiethyl amine induced multistage hepatocarcinogenesis with reference to lipid peroxidation and enzyme antioxidants. *Cell Bio chemistry and Function*, **19**: 27-35.
- Jeena, K.J., Joy, K.C. and Kuttan, R. 1999. Effect of *Emblica officinalis*, *phyllanthus amarus* and *picorrhiza kurroa* on N-nitrosodiethyl amine induced hepato carcinogenesis, *cancer Lett.* **136**:11-16.
- De Zwart, L.L., Meerman, J.H., Commandeur, J.N. and Vermeulen, N.P. 1999. Biomarkers of free radical damage applications in experimental animals and in humans. *Free Radical Biology and Medicine*, **26**: 202-2.
- Jose, K., Kuttan, R. and Bhattacharya, K. 1998. Effect of *Emblica officinalis* extract on hepatocarcinogenesis and carcinogen metabolism. *Journal of clinical Biochemistry and Nutrition*, **25**: 31-39.
- Spiteller, G. 1996. Enzymic lipid peroxidation – a consequence of cell injury? *Free Radical Biology and Medicine*, **21**: 1003-1009
- Gey, K.F. 1993. Prospects for the prevention of free radical disease, regarding cancer and cardiovascular disease. *British Medical Bulletin*, **49**: 679-99.
- Pompella, A., Romani, A. and Benditti, M. 1991. Comporti Lose of membrane protein thiols and lipid peroxidation of allyl alcohol hepatotoxicity. *Biochemical Pharmacology*, **41**: 1225-1259.
- Recknagel, R.O., Glende Jr. Dolak, J.A. and Waller, R.L. 1989. Mechanism of carbon tetrachloride toxicity. *Pharmacol. Ther.* **43**: 139-15.
- Abeleb, G.I. 1986. Production of embryonal serum alpha globulin by hepatomas: review of experimental and clinic data. *Cancer Res.* **28**: 1344-50.
- Buzby, G.P., Mullen, J.H., Stein, T.P. and Roasto, E.F. 1980. Host tumor interactions and nutrient supply. *Cancer*, **45**: 2940–2947.
- Galigher, A.E. and Kozloff, E.N. 1971. *Essentials of Practical Microtechnique*. Philadelphia: Lea & Febiger. 53.
- Nichaus, W.G. and Samuelson B. 1968. Formation of malondialdehyde from phospholipids arachidonate during microsomal lipid peroxidation. *Eur. J . Biochem*, **6**: 126-130.