



Histology and Histochemistry of Interstitial Tissue of Testes in Mountain (Gaddi) Goats- A Postnatal Developmental Study

Archana Pathak*

Department of Anatomy, College of Veterinary Science and Animal Husbandry, U.P. Pt. Deen Dayal Upadhyaya Pashu Chikitsa Vigyan Vishvavidyalaya Evam Go Anusandhan Sansthan Mathura, Uttar Pradesh, INDIA

*Corresponding author: A Pathak; E-mail: pathak_arcvik@yahoo.com

Received: 09 January, 2015

Accepted:

ABSTRACT

Testicular tissues obtained from 30 mountain (Gaddi) goats ranging from newborn to > 60 months age divided into 3 age groups viz; prepubertal (neonatal to < 18 month), pubertal (>18 months to <60 months) and postpubertal (>60 months) with at least 10 animals in each group were studied for histological and histochemical changes in their interstitium at various stage of development. The loose connective tissue comprised of various mesenchymal cells, fibroblasts, undifferentiated and differentiated Leydig cells-in various stages of development with capillaries and lymphatics filled up the interstices between the sex cords/ seminiferous tubules being more juvenile in neonates (with mesenchymal and young fibroblast cells) and mature (fibroblasts, fibrocytes and Leydig cells) in older animals. The latter also showed mononuclear cell infiltration as an autoimmune reaction of the ageing testicles. It contributed 65% of testicular tissues in neonates but 13-15% in pubertal and slightly less in postpubertal animals. Among the various cell types, Leydig cells were mostly PAS reactive. The Alcian Blue reaction was inconclusive, colloidal iron stained them mildly to moderately in neonates and prepubertal, moderately to strongly in pubertal and postpubertal groups. BPB reaction for protein and Feulgen for DNA was also strongly represented. Sudan black-B and oil red-O revealed an increasing trend with age. AKPase and ACPase activity was moderate in the Leydig cells.

Keywords: Interstitial tissue, leydig cells, Gaddi goat, testis

Gaddi goats are the dwellers of high hills of North Western Himalayas. These are reared by the tribals for food, fiber, leather and textiles. They are especially preferred for the quality lean meat and prolificity in breeding. These serve as the cash property of these nomadic tribes and also determine their social status. Breedability of male depends on the production of androgens by the interstitial cells of testes, which also affect the process of spermatogenesis. A number of researchers have detailed the morphology of these cells in various species of animals (Burgos *et. al.* 1970; Hooker, 1970; Connell and Connell, 1977, Gofur *et al.* 2008). Goat tissues particularly have been studied by Bordoloi (1979), Baishya *et.al.* (1987), Gupta (1989) and Karmore *et. al.* (2003). No literature is however available on these tissues of mountain goats. Since the environment and ambient (Lucier *et al.* 1977 and Leathem, 1977) have deep impact on the normal growth and maturation of gonads – a study on the postnatal development was

conducted in Gaddi goats - dwellers of the cold hilly ambient.

MATERIALS AND METHODS

Both testicles were dissected in situ and then excised out from thirty Gaddi goats at the municipal abattoir and veterinary polyclinic of HPAU, Palampur (4000 ft. from MSL, mid hill heavy rain fall zone) Himachal Pradesh; immediately after their sacrifice/death. The samples were classified in 3 age groups with 10 animals in each i.e. Group-I (zero day to 18 months), Group- II (> 18 months< 60 months) and Group-III (>60 months). During antemortem examination detailed enquiry was made regarding the actual age and sexual health of all the animals. After collection and quick gross examination, small pieces of testicular tissues were excised out and immersed in the fixatives viz; 10% neutral buffered formalin, Formal

acetic alcohol, Zenker's solution, Carnoy's fluid, Bouin's fluid and cold acetone as required for various histological and histochemical studies. Tissues were then processed for paraffin microtomy/cryotomy. Thin sections (5-10 μ) were stained with Haematoxylin and Eosin method for routine fibrocellular architecture, Van Gieson's method for Collagen fibers, Wilder's reticulum stain method and Gomori's reticulin method for Reticular fibers, Weigert's resocin fuchsin for Elastic fibers (Luna, 1968), Crossman's modification of Mallory's trichrome stain for Connective tissue (Crossman 1937), Periodic Acid Schiff reaction with and without saliva as well as diastase for Polysaccharides, Glycogen, Alcian Blue method (at pH 2.5) for Acid mucopolysaccharides (Luna 1968), Azodye method for Alkaline and Acid phosphatase (Barka and Anderson, 1963), Fettrot and oil red "O" method for Neutral fat, Bromophenol Blue method for Protein (Pearse, 1968), Sudan Black "B" in propylene glycol for lipid and Feulgen reaction for DNA (Davenport, 1960).

The relative proportions (% ratio) of the parenchymatous and stromal (connective) tissue at different ages were estimated by the images of tissues drawn with the help of the Ermascoppe with Lanometer over the standard tracing paper and then weighing the cut outs of the two components. At least 10 such observations were taken on each tissue from different groups and finally the percentage of interstitial tissue versus parenchymatous tissue was calculated.

RESULTS AND DISCUSSION

The interstitial tissue in the testes of neonatal kids/prepubertal goats lay between the non-luminated sex cords (Fig. 1) and luminated seminiferous tubules (Fig. 1 & 2).

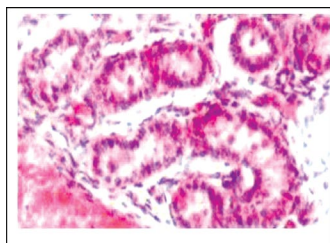


Fig. 1. Photomicrograph of testis of one day old gaddi kid showing highly vascularized interstitial tissues separating the sex cords. H & E \times 200

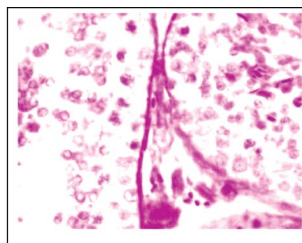


Fig. 2. Photomicrograph of testis of postpubertal gaddi goat showing pas reactive highly vacuolated cytoplasm of the interstitial cells pas \times 200

It was formed of loose areolar connective tissue of delicate fibrocellular nature. It comprised of mesenchymal cells, fibroblasts (juvenile and developing) in different stages of development, undifferentiated and differentiated Leydig cells, pervaded with capillaries and tissue spaces of variable expanse. The latter have been regarded as lymphatics by Burgos *et al.* (1970). The mesenchymal cells in neonatal testes were irregular in outline with weakly stained eosinophilic cytoplasm and lightly stained vesicular nucleus. In latter stages it turned into spindle shaped mesenchymal cells which are said to be the forerunners of the Leydig cells (Gondos, 1977). The fibroblasts were spindle shaped cells with darkly stained nuclei. They predominated over the other cells in number.

Undifferentiated Leydig cells were spindle shaped elongated or oval shaped cells. The eosinophilic cytoplasm appeared granular. Nuclei were eccentric, rounded or oval. They occurred in small groups of 2-3 cells between the fibroblasts (Fig. 3). The nuclear membrane was indistinct. The chromatin material was fine and uniformly distributed. The fusiform cells of intertubular tissue of man and opossum with similar nuclear morphology as observed in the present case were identified as the predecessors of the mature Leydig cells by Burgos *et al.* (1970). Further Gondos (1977) stated that the hypertrophied interstitial cells which were elongated and oval turned into Leydig cells. Occurrence of these different cells in interstitial tissue was in order with the description of Gondos (1977), who described their common origin from the gonadal mesenchyme of embryos. Bordoloi (1979) reported mesenchymal cells, mast cells, fibroblast and Leydig cells in the stroma of goats. The differentiated Leydig cells of goat testis were typical ovoid or roughly triangular or sometimes rounded in shape with highly vacuolated lightly stained eosinophilic granular cytoplasm. The rounded or ovoid nuclei of these cells were generally present eccentrically, towards the broader end of the cells. The nuclear membrane was distinct and the chromatin was coarser even sometimes dust like, distributed more towards the nuclear membrane. These cells occurred singly or sometimes in groups. Cytomorphologically these cells compared well with the mature interstitial or Leydig cells of cat, opossum and guinea pig (Hooker, 1970; Burgos *et al.* 1970). Gondos (1977) and Baishya *et al.* (1987) recorded the highest proliferation of differentiated Leydig cells in 16-30 days old Assam goat.

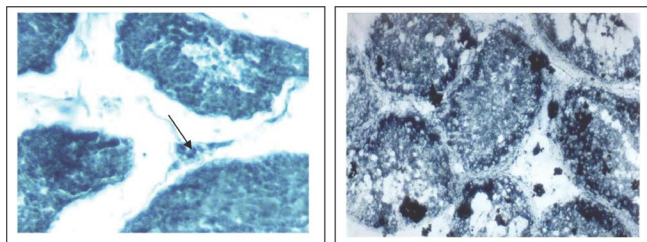


Fig. 3. Photomicrograph of testis of prepubertal Gaddi goat showing Sudan Black reaction in the interstitial cells (Arrow). Sudan black-B $\times 100$

Fig. 4. Photomicrograph of testis of pubertal Gaddi goat showing Sudan Black reaction in the interstitial cells Sudan black-B $\times 100$

In pubertal animals (>18 months to <60 months), the Leydig cells mostly dominated the other cell types. They occurred in groups of variable sizes and measured on an average $8.75 \pm 0.25\mu$ in diameter. Their nuclei measured 4-5 μ in diameter. Cytologically these cells were similar to the interstitial cells of Leydig of prepubertal group. Bordoloi (1979) stated that the Leydig cells were more in number and arranged in chains of 2-4 cells in the stroma of testes of adult goats. Karmore *et. al.* (2003) recorded 14.0 ± 0.79 cells per mm^2 in the testes of adult goats. The number of differentiated large Leydig cells in the intertubular area mildly increased in the postpubertal animals' (>60 months) testes, as compared to the prepubertal and pubertal animals. The cells measured $9.85 \pm 0.10\mu$ in diameter, while their nuclei measured 5.02 ± 0.3 in diameter. Hooker (1970) stated that the number of Leydig cells differed from species to species, being quite abundant in cat and pig but less numerous in guinea pig, mouse and man. Their size also varied in different species being much larger in bull and man than in mouse. A great number of Leydig cells have been reported to occur in summer lambs than in winter ones (Reviere *et. al.* 1984).

In neonatal kid testes, the interstitial tissue (area/volume) was much higher (65%) than the parenchyma (35%). In contrast, Fawcett *et. al.* (1973) reported 60% interstitial tissue in adult boar. This interstitial tissue: parenchyma ratio was reversed in elderly prepubertal goats' testes. At 6 months age, the interstitial tissue parenchyma ratio was 40:60 and at 12 months of age, it was further reduced 25:75. It became as low as 15:85 in 18 months old goats' testes, which corresponds to the ratio reported in adult dogs by

Kothari *et. al.* (1972). This indicated a faster growth rate of parenchyma than the interstitial tissue in order to meet the (spermatozoa) requirement of breeding goats at puberty (18 months and above). In pubertal animals it maintained its ratio (13:87). It was in order with the observation of Wrobel (1995) who observed 83% parenchyma and 17% interstitial tissue in adult German goats. Gupta (1989) observed fastest growth of parenchyma of Beetal goats during 12-18 months age. Fosslund (1954), Abdel Rouf (1960) and Deshpande *et. al.* (1985) reported 3-5 times increase in parenchyma of adult bovines and buffalo bulls at puberty. In the postpubertal animals due to degenerative changes in the seminiferous tubules, there was an overall reduction in the seminiferous tubules' diameter, which was followed by growth and proliferation of fibroblasts and infiltration of mononuclear cells in the interstitial tissue. Replacement of the seminiferous tubules by fibroblasts and giant cells resulted into reduction in overall size (volume) of the testes (Archana, 2006). Thus the percent ratio balance was nearly maintained. Leatham (1977) also reported the degenerative changes in the seminiferous tubules of mammals due to ageing- which was accompanied with intertubular fibrosis and increased tubular connective tissue. Increased mononuclear cells and fibroblasts can be associated with auto immune response of the tissue reaction (Bishop 1970). Fawcett *et. al.* (1973) observed the distribution pattern of the interstitial tissue in 14 species of animals and classified them into 3 categories one with small amount of interstitial connective tissue (1-5%) such as rat and mouse, second with the Leydig cells distribution through the loose connective tissue of interstitial tissue such as man, monkey, ram and bull and third with 20-60% of testicular volume occupied by only a little extra cellular space around. The Gaddi goats can thus be categorized into the 2nd category of animals as described by Fawcett *et. al.* (1973).

The results on the Histochemistry have been summarized in the table. The studies revealed mild to moderate degree of PAS reactivity in the cytoplasm of interstitial cells of Leydig cells (Fig. 2) whereas the other intertubular cells components were not reactive. Treatment with diastase revealed reduced intensities of staining, indicating thereby its being glycogen. The reaction was observed to be of a milder degree in the Best's carmine staining. The result was in conformity with that of Hooker (1970), Bordoloi and Dhingra (1983) in local goats of Haryana

Table 1. Histochemistry of Interstitial Tissue of Gaddi goats

Age group Components of Interstitial tissue Histochemical staining	Prepubertal		Pubertal		Postpubertal	
	Interstitial tubular cells	Leydig cells	Interstitial tubular cells	Leydig cells	Interstitial tubular cells	Leydig cells
PAS without diastase	-	±	-	+	-	+
Pas with diastase	-	-	-	±	-	±
Best's carmine	-	±	-	±	-	±
Alcian Blue (pH- 1.5)	-/+	-	-/+	-	-/+	-
Colloidal Iron	-	+	-	± to +	-	+ to ±
Sudan Black	-	+	-	++	-	++
Oil red -O	-	+	-	++	-	++
BPB	-	++	-	++	-	+++
DNA	-	+++	-	+	-	+
AKP	-	+	-	+	-	+
ACP	-	±	-	+	-	+

_ Negative; ± Inconsistent; + Mild; ++ Moderate; +++ Strong

and Burgos *et al.* (1970) in several species of mammals including rodents. The reaction for presence of AMPS was inconclusive. Alcian Blue (pH 2.5) reaction was of mild degree in the fibrocellular components other than the Leydig cells. Cytoplasmic component of the Leydig cells were negative for AMPS in all the age groups. The reaction for AMPS with the colloidal iron stain however showed a reversed trend.

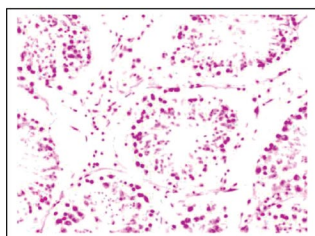


Fig. 5. Photomicrograph of testis of prepubertal Gaddi goat showing Feulgen's reaction in the interstitial cells. Feulgen's reaction × 100

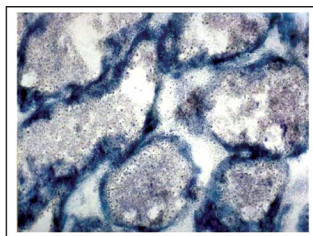


Fig. 6. Photomicrograph of testis of pubertal Gaddi goat showing intense AKPase reaction in the interstitial cells. (cryostat section)

It showed mild to moderate reaction in the Leydig cells of prepubertal and pubertal testes but moderate to strong reaction in postpubertal testes. Other intertubular components remained non-reactive. Sudan black-B and oil red-o stains showed a consistently increasing

concentration of cytoplasmic granules of interstitial cells (Fig. 3 & 4). It was mild in neonatal and moderate in prepubertal animals, but was strongly represented in the pubertal and postpubertal animals' testes. This probably indicated a stronger steroidogenic ability of these cells with onset of puberty. Hooker (1970) stated that Sudanophilic lipids have been observed by a number of workers in the Leydig cells of several species of animals including bull, ram, deer, boar and stallion. Further analysis of these components revealed them being cholesterol thus giving support to the steroidogenic function. Bilaspuri and Guraya (1983) have also revealed the Sudanophilic droplets of lipids and cholesterol in the Leydig cells of adult goats and rams of Punjab. Gupta (1989) also recorded an intense Sudanophilia in the Leydig cells of Beetal goats' testes at the age of 6-12 months (at puberty).

Lipid staining was not revealed in any other cell types of intertubular tissue. Bromophenol blue reaction for protein was also strongly represented in these interstitial cells. DNA staining was strongest in prepubertal, strong in pubertal and moderate in the postpubertal animal's Leydig cells (Fig. 5). Strongly basophilic reaction with methyl green and pyronin-Y staining and Fuchsinophilic granules have been reported in the Leydig cells of many species of animals (Hooker, 1970)

The alkaline phosphatase reaction was also moderately represented in the interstitial cells of Leydig in prepubertal and pubertal animals and inconsistently in older animals

(Fig. 6). The staining reaction for Acid phosphatase was however moderate in the pubertal and postpubertal animals but was of a lower intensity in the prepubertal age group. Phosphatases and other hydrolytic enzymes have been reported to occur in the cytoplasm of Leydig cells of many species of animals by several authors (Hooker, 1970).

REFERENCES

- Abdel-Rouf, M. 1960. The postnatal development of the reproductive organs in the bull with special reference to puberty (including growth of hypophysis and adrenal). *Acta. Endocrin., Copenhagen Supplement.*, **49**: 1-109.
- Baishya, G., Ahmed, S. and Bhattacharya, M. 1987. Leydig cells in the male gonads of Assam goat (*Capra hircus*) during early postnatal life. *Indian J. Anim. Health.*, **26**: 37-40.
- Barka, T. and Anderson, P.J. 1963. *Histochemistry: Theory, Practice and Bibliography*. Harper and Row. Publisher Inc. New York.
- Bilaspuri, G.S. and Guraya, S.S. 1983. Histo-chemical studies on lipids in the testis of buffalo, goat and ram. *Indian J. Anim. Sci.*, **53**: 818-823.
- Bishop, M.W. 1970. Ageing and reproduction in the male. *J. Reprod. fert. Suppl* **12**: 65-87.
- Bordoloi, C.C. 1979. Seasonal variations on the cytomorphological and cytochemical architecture of the testis in sexually mature male goats (*Capra hircus*). Ph.D. Thesis. Haryana Agricultural University, Hissar.
- Bordoloi, C.C. and Dhingra, L.D. 1983. Histological and certain histo-chemical studies on interstitial tissue of the testis of goat. *Haryana Agri. Uni. J. Res.*, **13**: 366-373.
- Burgos, M.H., Vitale-Calpe, R. and Aoki, A. 1970. Fine structure of the testis and its functional significance. In "The Testis" (A. D. Johnson, W.R. Gomes and N.L. VanDemark, eds.) Vol. 1, Academic Press, New York. Pp.551-649.
- Connell, C.J. and Connell, G.M. 1977. The interstitial tissue of the testis. In "The Testis" (A.D. Johnson and W.R. Gomes. Vol. IV, Academic Press, New York. Pp.333-370
- Crossman, G.A. 1937. A modification of Mallory's connective tissue stain with discussion of principles involved. *Anat. Rec.*, **69**: 33-38.
- Davenport, H.A. 1960. *Histological and histochemical technics*. W.B. Saunders Company, Philadelphia.
- Deshpande, B., Lalita, V. and Janakiraman, K. 1985. Histological changes in male gonads from birth to sexual maturity in buffaloes. *Indian J. Anim. Repro.*, **6** : 1-4.
- Fawcett, D.W., Neaves, W. and Flores, M.N. 1973. Comparative observations on intertubular lymphatics and the organization of the interstitial tissue of the mammalian testis. *Biol.Reprod.*, **9**: 500-532.
- Fossland, R.G. 1954. Histological development of the postnatal bovine testis. *J. Dairy Sci.* **37**: 669.
- Gofur, M.R., Khan, M.Z.I., Karim, M.R. and Islam, M.N. 2008. Histology and histomorphology of testis of indigenous bull (*Bos indicus*) of Bangladesh. *Bangl. J. Vet. Med.* **6**: 67-74.
- Gondos, B. 1977. Testicular Development. In "The Testis". (A.D. Johnson and W.R. Gomes. eds.) Vol. IV. Academic Press, New York. Pp 1-29.
- Gupta, A.N. 1989. Correlative anatomy of the testes, epididymis and accessory sex glands in goat. Ph.D Thesis Haryana Agricultural University, Hissar.
- Hooker, C.W. 1970. The intertubular tissue of the testis. In "The Testis" (A.D. Johnson, W.R. Gomes and N.L. VanDemark, eds.) Vol. 1., Academic Press, New York. Pp.483-550
- Karmore, S.K., Bhamburkar, V.R., Dalvi, S.S., Banubakode, S.B. and Nandeshwar, N.C. 2003. Histomorphology of testis of goat (*Capra hircus*). *Indian J. Anim. Sci.*, **73**: 187-189.
- Kothari, L.K., Srivastva, D.K., Mishra, P. and Patni, M.K. 1972. Total Leydig cell volume and its estimation in dogs and in models of testis. *Anat. Rec.*, **174**: 259-264.
- Leathem, J.H. Temperature and Seasonal influences. 1977. In "The Testis". (A.D. Johnson and W.R. Gomes, eds.) Vol. IV, Academic Press, New York. pp. 517-546.
- Lucier, G.W., Lee, I.P. and Dixon, R.L. 1977. Effects of environmental agents on male reproduction. In "The Testis" (A.D. Johnson and W.R. Gomes, eds.) Vol. IV, Academic Press, New York. pp. 578-604.
- Luna, L.G. 1968. Manual of Histological staining methods of the armed Forces Institute of pathology. 3rd ed. McGraw Hill Book Company, New York.
- Pathak, A. 2006. Correlative anatomy of the testis and accessory sex glands of Gaddi goat (*Capra hircus*). Ph.D. Thesis. Pt. DDU Pashu Chikitsa Vigyan Visvavidyalaya Evam Go Anusandhan Sansthan (DUVASU)-Mathura.
- Pearse, A.G.E. 1968. *Histochemistry Theoretical and Applied*. Vol. I, J. and A. Churchill Limited, 104, Gloucester Palace, London.
- Reviere, M.T.H-de., Land, R.B., Perreau, C., Thompson, R. and Hochereau-de-Reviere M.T. 1984. Effect of season of birth and of hemicastration on the histology of the testis of 6 months old lambs. *J. Repro. Fert.*, **70**: 157-163.
- Wrobel, K.H., Reichold, J. and Schimmel, M. 1995. Quantitative morphology of the ovine seminiferous epithelium. *Ann. Anat.*, **177**: 19-32.

