



Comparative Gross Anatomy of the Sternum in Peacock (*Pavo cristatus*), Turkey (*Meleagris gallopavo*), Duck (*Anas platyrhynchos*) and White-breasted waterhen (*Amaurornis phoenicurus*)

Archana Pathak*, S.K. Gupta, Abhinav Verma, M.M. Farooqui, Ajay Prakash and Prabhakar Kumar

Department of Anatomy, College of Veterinary Science and Animal Husbandry, DUVASU, Mathura, (U.P.), INDIA

*Corresponding author: A Pathak; E-mail: pathak_arcvik@yahoo.com

Received: 03 Jan., 2017

Revised: 11 May, 2017

Accepted: 14 May, 2017

ABSTRACT

Comparative gross anatomical studies were conducted on the sternum of peacock, turkey, duck and white breasted waterhen. In peacock and turkey the sternum was quadrilateral strongly concave plate like whereas, in duck and white-breasted waterhen, it was rectangular in shape. The spina sterni was large, quadrilateral in shape with a large foramen at its root in peacock and turkey. In duck and white breasted waterhen the spina sterni was pointed and no foramen was present in it. Processus lateralis cranialis was hamulus shape, directed cranio-laterally and did not extend up-to the spina sterni in peacock, whereas in turkey it was dagger shaped, extended beyond the apex of spina sterni. In duck, the processus lateralis cranialis was hook like and lag behind the spina sterni. In white breasted waterhen it was large, triangular shaped and extended up-to the base of spina sterni. In peacock, two foramen pneumaticum medianum were present on the mid line at the dorsal surface of body of sternum. In duck single median pneumatic foramen was present on the mid line close to anterior border of sternum. The processus thoracicus was absent in duck and white breasted waterhen. The processus caudalis lateralis was long and narrow, widened out in its terminal in peacock and turkey, but in duck and white-breasted waterhen, the process was clasp like. In peacock, turkey and duck this process did not reach up-to the caudal end of the metasternum but in white-breasted waterhen, it reached beyond the caudal end of the metasternum.

Keywords: Anatomy, sternum, peacock, turkey, duck, white-breasted waterhen

Anatomy of sternum in domestic fowl has been described by Sisson (1953) and Bradley and Grahame (1960). Nickel *et al.* (1977) further added on the comparative features of sternum in fowl along with pigeon and goose. The information on the sternum of peacock, a low flight birds and turkey, duck and white-breasted waterhen, the poor flight birds are still need. Therefore the study has been undertaken to record the comparative anatomical features of the sternum in these (peacock, turkey, duck and white-breasted waterhen) birds.

MATERIALS AND METHODS

The carcasses of peacock, turkey and duck one each were procured from the Department of Pathology, DUVASU, Mathura where these were brought for the postmortem

examination. The carcass of white-breasted waterhen was procured from the field where it lay dead due to severe cold. The carcasses were macerated for bone recovery. The bones were then cleaned and sun dried for further anatomical studies.

RESULTS AND DISCUSSION

The sternum was an extensive bone, which forms the floor of the thoracic cavity and a greater part of the abdominal cavity of fowl (Sisson, 1953). It was a quadrilateral curved plate with processes projecting from each angle and from the middle of the cranial and caudal borders (Bradley and Grahame, 1960; Sisson, 1953). In peacock (Fig. 2A) and turkey (Fig. 2B) the sternum was quadrilateral strongly concave plate as also described in fowl (Nickel *et al.*,

1977), ostrich (Predoi *et al.*, 2009) and Pariah kite (Tomar *et al.*, 2011), but in duck (Fig. 2C) and white-breasted waterhen (Fig. 2D), it was rectangular in shape as also described by Nickel *et al.* (1977) and Jaychitra *et al.* (2015) in duck. The caudal medial projection, the metasternum was long and narrow in peacock and turkey as also in fowl (Bradley and Grahame, 1960) but in peacock it was shallow and gradually became narrow and terminated into a blunt pointed end while in turkey it was deeply concave like a spoon, narrow cranially and wider caudally and terminated into a rounded end. In duck the metasternum was rectangular whereas, in white breasted waterhen it was triangular in shape. From the ventromedial aspect of the body of sternum a tall plate like ridge, the sternal crest was present in all the four species as described in fowl (Bradley and Grahame, 1960; Nickel *et al.*, 1977; Sisson, 1953), Green winged macaw (Sreeranjini *et al.*, 2015) and duck and turkey (Jaychitra *et al.*, 2015). Jaychitra *et al.*

(2015) further reported an absence of the sternal crest in emu's sternum. In peacock (Fig. 1A), turkey (Fig. 1B), duck (Fig. 1C) and white-breasted waterhen (Fig. 1D) the sternal crest was an elongated triangle, the apex of which extended to the caudal end of the breast bone as in fowl (Nickel *et al.*, 1977), turkey and duck (Jaychitra *et al.*, 2015). In the spot billed pelicans, the sternal crest extended only up-to the cranial half and beyond which the ventral surface was free (Sathyamoorthy *et al.*, 2012b). On the other hand in white rumped vultures, the sternal crest originated one inch caudal to the cranial border and terminated about one cm cranial to the caudal end (Sathyamoorthy *et al.*, 2012a). In peacock (Fig. 1A) and turkey (Fig. 1B), the sharp cranial end of the crest was concave, almost semilunar in shape and did not reach to the cranial border of the sternum as described in fowl and pigeons (Nickel *et al.*, 1977). In white-breasted waterhen also the cranial border was concave, semilunar shape and

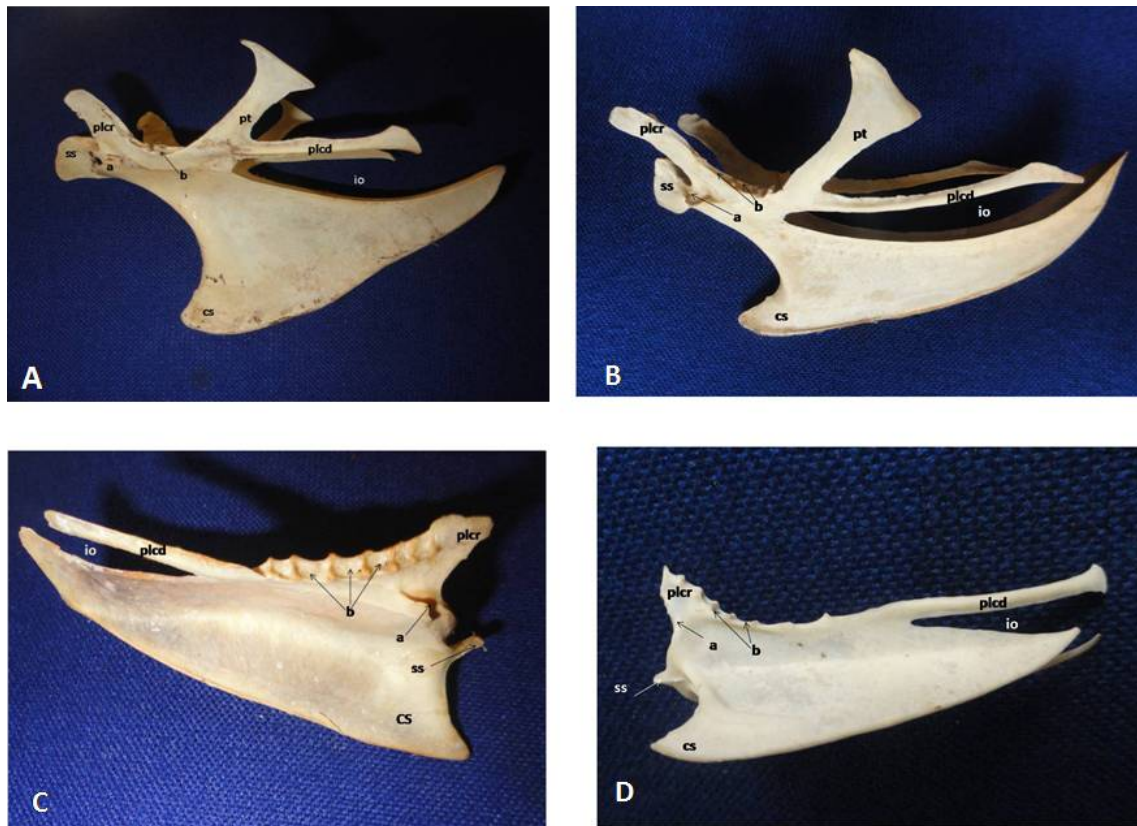


Fig. 1: Lateral view of sternum of peacock (A), turkey (B), duck (C) and white-breasted waterhen (D) showing crista sterni (cs), spina sterni (ss), processus lateralis cranialis (plcr), processus lateralis caudalis (plcd), processus thoracicus (pt), foramen ovale (io), facet for articulation with coracoids bone (a), facet for articulation with rib (b).

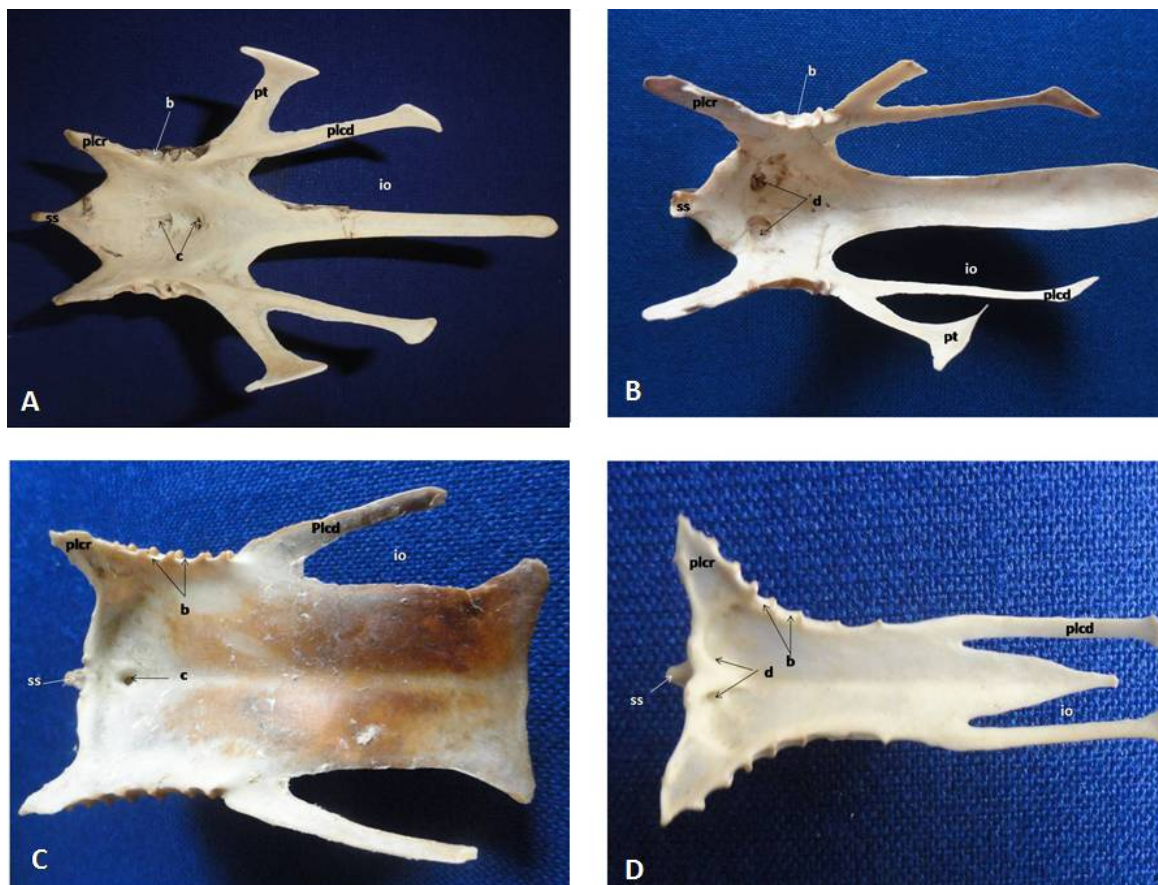

Fig. 2: Dorsal view of sternum of peacock (A), turkey (B), duck (C) and white-breasted waterhen showing crista sterni (cs), processus lateralis cranialis (plcr), processus lateralis caudalis (plcd), processus thoracicus (pt), foramen ovale (io), facet for articulation with rib (b), foramen pneumaticum medianum (c), foramen pneumaticum (d).

slightly away from the cranial border of the sternum (Fig. 1D). In duck, the anterior border of the crest was slightly concave which is in contrast to the observation of Nickel *et al.* (1977) who described it straight in duck and goose. The sharp cranial end of the crest extended slightly forward to the cranial end of the sternum.

In turkey the ventral border of the sternal crest was thick in its anterior 1/3rd part, sharp and almost straight in its middle and steeply curved in its terminal part. In peacock, the ventral border of the sternal crest was thick and convex in its anterior 2/3rd part, became slightly concave in the middle and straight in its terminal part. It made a steep caudally directed arch as in pigeon (Nickel *et al.*, 1977). In duck, the ventral border of sternal crest was almost straight. In contrast Nickel *et al.* (1977) described it concave. In white-breasted waterhen, the ventral border of

sternal crest was sharp, straight and made a steep caudally directed arch as in pigeon (Nickel *et al.*, 1977) and macaw (Sreeranjini *et al.*, 2015).

In all the four species of the birds there was a deep convex groove with sharp edges which followed the thickened convex cranial border of the sternum to receive the cylindrical distal end of the coracoid bones as described by Nickel *et al.* (1977). In turkey (Fig. 1B) and peacock (Fig. 1A) two processes arose from the dorsal and ventral edges of the groove which fused into a median vertical bony plate, the spina sterni, leaving an opening between them as in fowl (Nickel *et al.*, 1977). Whereas in duck (Fig. 1C) and white breasted waterhen (Fig. 1D) only the ventral process was present and it formed a single pointed projection as also described earlier in duck and goose (Nickel *et al.*, 1977). In duck and white breasted

waterhen, the opening was absent. Jaychitra *et al.* (2015) also reported the absence of this opening in duck. The spina sterni of peacock was a large quadrilateral plate with thickened dorsocranial border, thin and sharp ventral border (Fig. 1A), whereas in turkey it was relatively smaller quadrilateral shaped plate with straight ventral border (Fig. 1B).

In all the four species of bird studied viz; peacock, turkey, duck and white-breasted waterhen the processus lateralis cranialis arose from the sternum as a craniolaterally directed flat projection lateral to the articular surface for coracoid as described by Nickel *et al.* (1977) in fowl and pigeon. This processus was hamulus shaped directed craniolaterally and did not extend up-to spina sterni in peacock (Fig. 1A and 2A), in turkey it was dagger shaped directed craniolaterally and extended beyond the apex of the spina sterni (Fig. 1B and 2B). In duck the process was hook shaped and ended before the spina sterni (Fig. 1C and 2C). In white-breasted waterhen, it was relatively large triangular shaped directed craniolaterally and extended up-to the base of spina sterni (Fig. 1D and 2D).

Nickel *et al.* (1977) mentioned that this process was very large in fowl, very short in pigeon and small in duck and goose. Following caudally on the thickened lateral border of the sternum lay the articular surfaces for the sternocostal ribs in all the four species of the birds as also in fowl (Nickel *et al.*, 1977). In peacock (Fig. 1A and 2A) and turkey (Fig. 1B and 2B) four distinct articular surfaces were present for the sternocostal ribs, which were further having pneumatic foramen as in fowl (Nickel *et al.*, 1977). In duck, the lateral thickened border was having seven well formed articular surfaces (Fig. 1C and 2C) with pneumatic foramen only in few of them.

In white-breasted waterhen the lateral border was thick cranially, thin caudally and had seven distinct articular surfaces (Fig. 1D and 2D) without any pneumatic foramen. A part from numerous small air holes known as foramina pneumatica, the two large foramen pneumatica mediana were present along the midline on dorsal surface of the body of sternum in peacock (Fig. 2A) as in fowl (Nickel *et al.*, 1977). These were however more caudally placed than in fowl. In turkey the median pneumatic foramen was not found however several large and small foramina pneumatica were present on either side of the midline of body of sternum (Fig. 2B) as reported by Jaychitra *et al.*

(2015). In duck a strikingly distinct foramen pneumaticum medianum was present close to the anterior border of the sternum (Fig. 2C) but other foramina pneumatica were not found on the dorsal surface of the sternum. Jaychitra *et al.* (2015) reported that the dorsal surface of body of sternum of duck was pierced by numerous small foramina. In white-breasted water hen, the foramen pneumaticum medianum was not present but two small foramina pneumatica were present on either side of midline near the cranial border of the body of sternum (Fig. 2D).

A caudo-laterally directed processus caudalis lateralis arise from each side of the body of sternum in all the four species of the birds as also described in fowl (Nickel *et al.*, 1977; Bradley and Grahame, 1960). In peacock (Fig. 1A and 2A) and turkey (Fig. 1B and 2B) this process was long and narrow, widened out in its terminal part as also in fowl (Nickel *et al.*, 1977).

In duck (Fig. 1C and 2C) and white-breasted waterhen (Fig. 1D and 2D), the process was clasp like as described by Nickel *et al.* (1977) in duck and goose. Further in peacock, turkey and duck the process did not reach up-to the caudal end of the middle piece of sternum (Fig. 2A, 2B and 2C) (metasternum) as in fowl (Nickel *et al.*, 1977) but in white-breasted waterhen, the process reached beyond the caudal end of the metasternum (Fig. 2D). In peacock, turkey and white-breasted waterhen this process ran more or less parallel with the middle piece of the sternum. The foramen ovale was present as an oval notch between the middle piece of sternum and processus caudalis lateralis in all the four species studied as also described by Nickel *et al.* (1977). This foramen ovale was however much wider in peacock (Fig. 2A), turkey (Fig. 2B) and duck (Fig. 2C) than in white-breasted waterhen (Fig. 2D) where it was quite narrow.

A processus thoracicus arose with the processus caudalis lateralis in peacock (Fig. 1A and 2A) and turkey (Fig. 1B and 2B) as also in fowl (Nickel *et al.*, 1977). This process broadened towards its free end and covered the sternal segment of the last two ribs as in fowl (Bradley and Grahame, 1960). In duck and white-breasted waterhen, the processus thoracicus was absent (Fig. 2C and 2D).

REFERENCES

- Bradley, O.C. and Grahame, T. 1960. *The structure of the fowl*. 4th ed., Oliver and Boyd Ltd. Edinburgh and London.

- Jaychitra, S., Balasundaram, K. and Paramasivan, S. 2015. Comparative anatomical studies on the sternum of emu, turkey and duck. *Indian J. Vet. Anat.*, **27**(1): 61-64.
- Nickel, R., Schummer, A. and Seiferlie, I. 1977. *The skeletal system. Bones of pelvic limb*, "Anatomy of the Domestic Birds". pp 10-12, Verlag Paul Parey, Berlin.
- Predoi, G., Belu, C., Dumitrescu, I., Georgescu, B., Seiearu, A., Rosu, P., Carmen, B. and Dumitrescu, F. 2009. Comparative researches regarding the sternum in ostrich (*Struthio camelus*) and Nandu (*Rhea Americana*). *Lucrari Sci. Med. Vet.*, **42**: 342-346.
- Sathyamoorthy, O.R., Thirumurgan, R. and Rajan Palanivel, M. 2012b. Gross anatomical studies on the sternum and ribs of white-rumped vultures (*Gyps bengalensis*). *Indian J. Vet. Anatomy*, **24**(2): 106-108.
- Sathyamoorthy, O.R., Thirumurgan, R., Kumar Senthil, K. and Jayathangaraj, M.G. 2012 a. Gross anatomical studies on the sternum and clavicle of spot-billed pelican (*Pelecanus philippensis*). *Tamil Nadu J. Vet. Anim. Sci.*, **8**(3): 166-170.
- Sisson, S. 1953. The Skeleton of the chicken "The Anatomy of the Domestic Animals". W.B. Saunders, Philadelphia.
- Sreeranjini, A.R., Ashok, N., Indu, V.R., Lucy, K.M. and Chungath, J.J. 2015. Gross anatomical features of the sternum of green-winged macaw (*Ara Chloroptera*). *Indian J. Anim. Res.*, **49**(6): 860-862.
- Tomar, M.P.S., Vaish, R., Parmar, M.L., Shrivastva, A.B. and Tiwari, Y. 2011. Gross morphometrical studies of sternum of Pariah Kite (*Milvus migrans*). *Vet. World*, **4**(4): 171-172.

