



Morphological and Morphometrical Study on Oesophagus of Japanese Quail (*Coturnix japonica*)

Rupam Sinha, Prabhakar Kumar, Aditya Kumar and Yousuf Dar

Department of Veterinary Anatomy, College of Veterinary & Animal Sciences, S.V.P. University of Agriculture & Technology,
Meerut (U.P.), INDIA

*Corresponding author: P Kumar; E-mail: prabhakar.anatomy@gmail.com

Received: 10 May, 2023

Revised: 25 May, 2023

Accepted: 04 June, 2023

ABSTRACT

Present study was conducted on esophagus of seven adult Japanese Quail. The oesophagus of Japanese quail was thin walled distensible tube comprised of three distinct segments namely precrop oesophagus (cervical part), crop and postcrop oesophagus (thoracic part). The crop was form a rounded structure at the level of thoracic inlet, that bulged further ventrally to the right and lied against the pectoral muscles. The postcrop oesophagus was relatively longer, wider and more distensible as compared to precrop oesophagus. The interior of oesophagus presented longitudinal mucosal folds which were prominent in precrop oesophagus and crop as compared to postcrop oesophagus. These muscosal folds were longitudinal in precrop oesophagus and were wavy in crop.

HIGHLIGHTS

- Detailed topographical and morphological study of oesophagus in Japanese Quail.
- Detailed morphometrical study of oesophagus in Japanese Quail

Keywords: Morphological, morphometrical, oesophagus, Japanese Quail

The Japanese Quail is a small sized bird, native to the Indo-China continental region including Japan. After second world war Quail meat industry was revived from remaining survivors in the post-war period (Wetherbee, 1961). Now a days, Japanese Quail in poultry industry is expanding on a global scale providing an alternative food, vitamin and protein source with low inputs, thus these qualities have made Japanese quail a popular model species for scientific studies (Rundfeldt *et al.*, 2013). The oesophagus is an important tubular organ of digestive tract that conveys food to the stomach. Although the intestinal morphology of Japanese Quail has been extensively (Rodler and Sinowatz, 2013; Wilkinson *et al.*, 2018), little attention has been paid towards the morphological and mophometrical studies of oesophagus in this species. So, the study was planned to document the normal anatomical features of oesophagus along with its morphometry in Japanese Quail.

MATERIALS AND METHODS

The experiment was conducted on seven apparently healthy adult Japanese Quail of either sex reared at the Poultry Research & Training Center, SVPUAT, Modipuram, (U.P). The adult birds were sacrificed by severing the carotid artery and jugular vein. After careful dissection the topographical and morphological features of oesophagus was recorded and then the organ was taken out for its morphometry. The length and diameter was recorded with the help of thread and digital Vernier calipers, the weight was measured using analytical balance (Sartorius, TE 214S). The volume of the organ was measured by water

How to cite this article: Sinha, R., Kumar, P., Kumar, A. and Dar, Y. (2023). Morphological and Morphometrical Study on Oesophagus of Japanese Quail (*Coturnix japonica*). *J. Anim. Res.*, 13(03): 387-391.

Source of Support: None; **Conflict of Interest:** None



displacement method. After recording the morphometrical parameters the organ was incised and examined under stereozoom microscope (Optica, Italy) to record its internal features.

RESULTS AND DISCUSSION

The oesophagus of Japanese quail was thin walled distensible tube comprised of three distinct segments namely precrop oesophagus (cervical part), crop and postcrop oesophagus (thoracic part) (Fig. 1) similar findings were observed in Fowl (Dellman *et al.*, 1976).

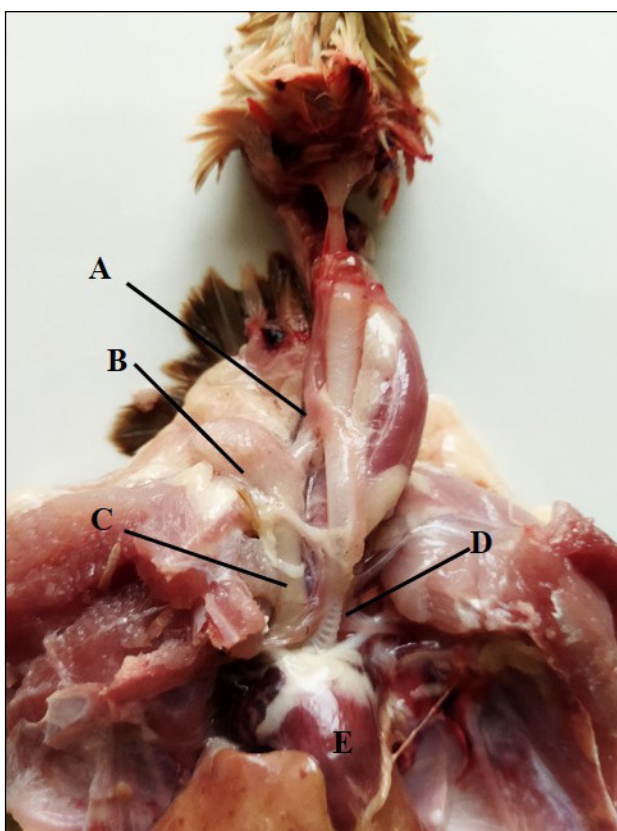


Fig. 1: Photograph of dissected Japanese quail showing precrop esophagus (A) crop (B) post crop esophagus (C) and trachea (D)

However, Saran *et al.* (2019) in Guinea fowl; Elshaer (2018) in Kingfisher; Kadhim and Mohamed (2015) in Homing Pigeon and Zhu (2015) in Grey-Backed Shrike reported that the esophagus consisted of two sections depending upon the portion located in particular region viz. cervical esophagus and thoracic esophagus. The average length, diameter, weight and volume of

oesophagus was 73.22 ± 4.06 mm, 1.77 ± 0.21 gm and 1.71 ± 0.32 ml, respectively (Table 1).

Table 1: Length (mm), diameter (mm), weight (gm) and volume (ml) of oesophagus and its parts in Japanese quail (Mean \pm SE)

Parameters	Japanese Quail
Length of oesophagus (mm)	73.22 ± 4.06 (60.12—88.66)
Weight of esophagus (gm)	1.77 ± 0.21 (1.04—2.41)
Volume of esophagus (ml)	1.71 ± 0.32 (1.10—3.25)
Length of precrop oesophagus (mm)	28.96 ± 2.21 (20.93—35.29)
Diameter of precrop oesophagus (mm)	4.30 ± 0.36 (3.01—6.58)
Length of postcrop oesophagus (mm)	30.73 ± 1.33 (27.97—36.25)
Diameter of postcrop oesophagus (mm)	5.35 ± 0.58 (4.35—7.58)
Length of crop (mm)	13.82 ± 0.67 (12.23—17.12)
Diameter of crop (mm)	17.82 ± 0.61 (15.90—21.04)

The precrop oesophagus began from dorsal aspect of trachea, soon attained right side of trachea and maintained this relation till thoracic inlet. At the level of thoracic inlet, the ventral wall of the esophagus was greatly expanded to form a rounded structure, the crop that bulged further to the right and lied against the pectoral muscles (Fig. 2). This was in agreement with the findings of Zaher *et al.* (2012) in *Coturnix coturnix* and Malewitz and Calhoun (1957) in Turkey. While Al-Juboory *et al.* (2015) showed that the initial part of the oesophagus began with the end of the oropharynx and intertwined on the trachea. However, the crop was spindle shaped in Guinea fowl Saran *et al.* (2019) and Homing pigeon Kadhim and Mohamed (2015). The diameter and length of crop was 17.82 ± 0.61 mm and 13.82 ± 0.67 mm, respectively (Table 1). The postcrop oesohagaus coursed on right dorso-lateral aspect of trachea, then attained mid dorsal position of tracheal bifurcation crossed it to open into the proventriculus

slightly left of the midline (Fig. 2). Kadhim and Mohamed (2015) in Homing Pigeon and Dyce *et al.* (1965) in Fowl reported that the thoracic esophagus was placed below the crop and opened directly into the proventriculus within thoraco-abdominal cavity, to the left side of the median plane closely related to the cervical, clavicular and anterior thoracic air sacs while Madhu *et al.* (2015) reported in Emu that thoracic esophagus passed dorsal to the bronchi and open into proventriculus at the level of 5th vertebral rib.

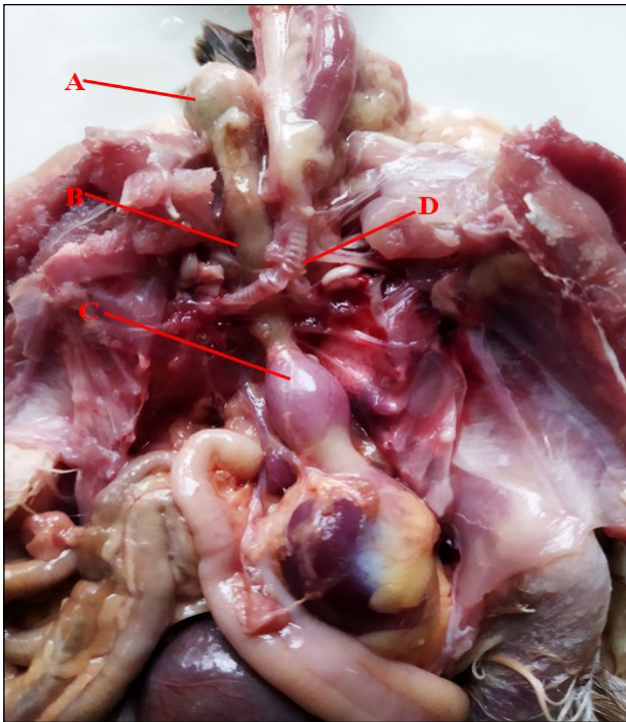


Fig. 2: Photograph of dissected Japanese quail showing precrop crop (A) post crop esophagus (B) Proventriculus (C) and tracheal bifurcation (D)

The postcrop oesophagus was relatively longer, wider and more distensible as compared to precrop oesophagus. The length and diameter of precrop oesophagus was 28.96 ± 2.21 mm and 4.30 ± 0.36 mm, respectively whereas for postcrop oesophagus the same were 30.73 ± 1.33 mm and 5.35 ± 0.58 mm, respectively (Table 1). The diameter of precrop oesophagus was maximum at beginning that gradually reduced till the level of thoracic inlet, however, the diameter of postcrop oesopgaus was almost equal throughout its course except at its termination before the proventriculus where it decreased abruptly (Fig. 3). The

relatively longer and broader postcrop oesophagus than post crop esophagus accounted for the herbivorous feeding habit as reported in Common Quail (Klasing, 1999; Parchami and Dehkordi, 2011) and Quail (Zaher *et al.*, 2012). In contrast Kadhim and Mohamed (2015) in Homing pigeons and Saran *et al.* (2019) in Guinea Fowl observed that the diameter of lumen of cervical esophagus was greater than that of thoracic esophagus in both male and female.

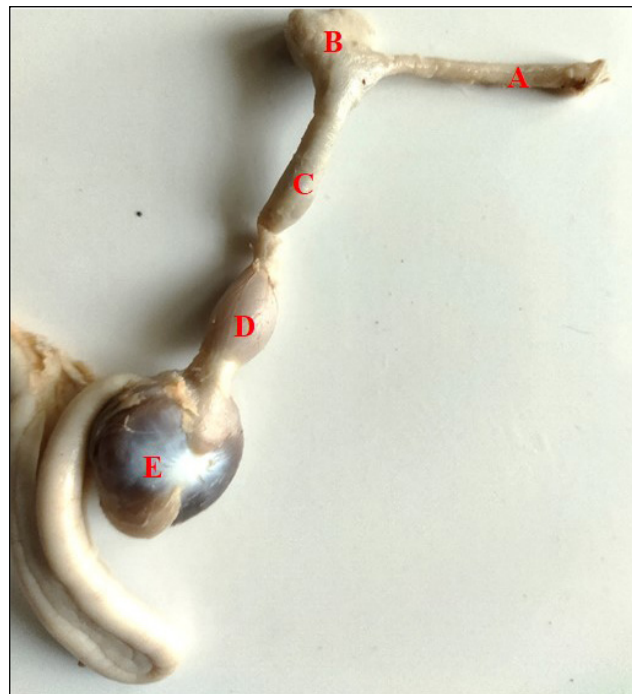


Fig. 3: Photograph showing precrop esophagus (A) crop (B) post crop esophagus (C) and proventriculus (D) and gizzard (E) of Japanese quail

The interior of oesophagus presented numerous longitudinal mucosal folds which were prominent and grossly visible in precrop oesophagus (Fig. 4) and crop (Fig. 5), however, these were not grossly observable in postcrop oesophagus. Under stereozoom microscope, the mucosal folds were very prominent in precrop oesophagus (Fig. 6) and faint in postcrop oesophagus (Fig. 7). These mucosal folds were longitudinal in precrop oesophagus (fig.4) and were wavy in crop (Fig. 5). These longitudinal folds provide ability to distend the oesophagus for easy passage of food and store food particles in the crop (Rodrigues and Choct, 2018). The postcrop oesophagus continued posteriorly with proventriculus without any

clearcut demarcation. The oesophagus opened into the proventriculus slightly left of the median plane (Fig. 2) and was closely related to the cervical, clavicular and anterior thoracic air sacs at the level of 4th vertebral rib without clear demarcation.



Fig. 4: Photograph showing prominent longitudinal mucosal folds (arrow) in precrop esophagus

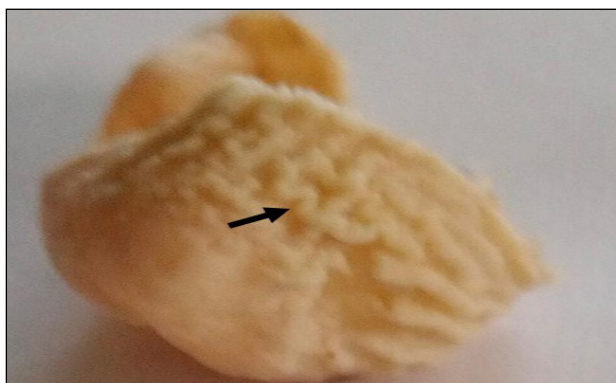


Fig. 5: Photograph showing prominent wavy mucosal folds (arrow) in crop

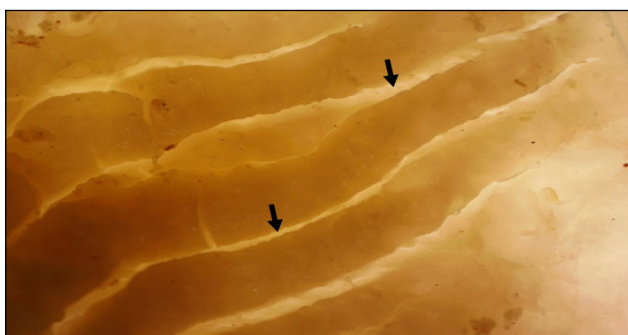

Fig. 6: Microphotograph showing prominent longitudinal mucosal folds (arrow) in precrop esophagus (Under stereozoom microscope)

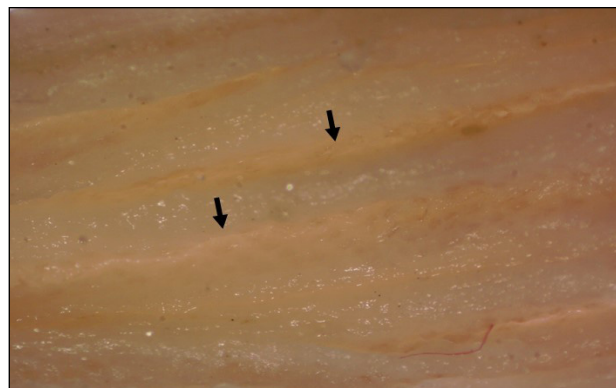

Fig. 7: Microphotograph showing faint mucosal folds (arrow) in postcrop esophagus (Under stereozoom microscope)

CONCLUSION

From the study it was observed that the oesophagus of Japanese quail was a distensible tube between oropharynx and stomach and consisted of three parts namely, precrop oesophagus, crop and postcrop oesophagus. The postcrop oesophagus was relatively longer, wider and more distensible as compared to precrop oesophagus. Interior of oesophagus presented mucosal folds which were prominent and longitudinal in precrop oesophagus, wavy in crop and less prominent in postcrop oesophagus.

ACKNOWLEDGEMENTS

Authors are thankful to the Vice Chancellor of SVPuat and Dean, COVAS for allowing to conduct research work.

REFERENCES

- Al-Juboory, R.W., Daoud, H.A.M. and Al-Arajy, A.S. 2015. Comparative anatomical, histological and histochemical studies of the oesophagus in two different Iraqi birds (*Columba palumbus* and *Tyto alba*). *Int. J. Adv. Res. Biol. Sci.*, **2**(12): 188–199.
- Dellman, H.D. 1976. Text book of Veterinary Histology. 4th edn. Blackwell Publishing, Ames, Iowa, USA., pp. 192-193.
- Dyce, K.M., Sack, W.O. and Wensing, C.J.G. 1965. Textbook of Veterinary Anatomy. 2nd edn W.B. Saunders Comp. Philadelphia. London. Toronto Montreal. Sydney, pp. 822-823.
- Elshaer, F.M. 2018. Morphometric studies of the esophagus and stomach in two types of birds have different feeding behaviors. *Egypt. Acad. J. Biol.*, **10**(2): 91- 97.

- Kadhim, K.H. and Mohamed, A.A. 2015. Comparative anatomical and histological study of the esophagus of local adult male and female homing pigeon (*Columba livia domestica*). *AL-Qadisiya J. Vet. Med. Sci.*, **14**(1): 80-86.
- Klasing, K.C. 1999. Avian gastrointestinal anatomy and physiology. *Semin. Avian Exotic. Pet. Med.*, **8**: 42-50.
- Malewitz T.D. and Calhoun M.L. 1957. The gross and microscopic anatomy of the digestive tract, spleen, kidney, lungs and heart of the Turkey. *Poultry Sci.*, **37**: 388-398.
- Madhu, N., Balasundaram, K., Paramasivan, S., Jayachitra, S., Vijayakumar, K. and Tamilselvan, S. 2015. Gross Morphology and Histology of oesophagus in Adult Emu Birds (*Dromaius novaehollandiae*). *Asian J. Sci. Tech.*, **6**(1): 969-971.
- Parchami, A. and Dehkordi, R.A.F. 2011. Histological characteristics of the esophageal wall of the common quail (*Coturnix coturnix*). *World Appl. Sci. J.*, **14**(3): 414-419.
- Rodler, D. and Sinowatz, F. 2013. Expression of intermediate filaments in the Balbiani body and ovarian follicular wall of the Japanese quail (*Coturnix japonica*). *Cells Tissues Organs*, **197**: 298-311.
- Rodrigues, I. and Choct, M. 2018. The foregut and its manipulation via feeding practices in the chicken. *Poultry Sci.*, **97**(9), 3188–3206.
- Rundfeldt, C., Wyska, E., Steckel, H., Witkowski, A., Jezewska-Witkowska, G. and Wlaz, P. 2013. A model for treating avian aspergillosis: serum and lung tissue kinetics for Japanese quail (*Coturnix japonica*) following single and multiple aerosol exposures of a nanoparticulate itraconazole suspension. *Med. Mycol.*, **51**: 800-810.
- Saran, D., Meshram, B., Joshi, H., Singh, G. and Kumar, S. 2019. Gross Morphological Studies on the Digestive System of Guinea Fowl (*Numida meleagris*). *Int J. Live. Res.*, **9**(2): 266-273.
- Wilkinson, N., Dinev, I., Aspden, W.J., Hughes, R.J., Christiansen, I., Chapman, J., Gangadoo, S., Moore, R.J. and Stanley, D. 2018. Ultrastructure of the gastro intestinal tract of healthy Japanese quail (*Coturnix japonica*) using light and scanning electron microscopy. *Animal Nutr.*, **4**: 378-387.
- Wetherbee, D.K. 1961. Investigations in the life history of the common Coturnix. *Am. Midl. Nat.*, **65**: 168-86.
- Zaher, M., El-Ghareeb, A.W., Hamdi, H. and Abu-Amod, F. 2012. Anatomical, histological and histochemical adaptations of the avian alimentary canal to their food habits: I- *Coturnix coturnix*. *Life Sci. J.*, **9**(3): 253-275
- Zhu, L. 2015. Histological study of the oesophagus and stomach in grey-backed shrike (*Lanius tephronotus*). *Int. J. Morphol.*, **33**(2): 459- 461.

