



SHORT COMMUNICATION

Morphological Studies on the Mandible of Local Pig (Zovawk) of Mizoram

O.P. Choudhary*, P.C. Kalita, P.J. Doley and A. Kalita

Department of Veterinary Anatomy and Histology, College of Veterinary Sciences and Animal Husbandry, Central Agricultural University, Selesih, Aizawl, Mizoram, INDIA

*Corresponding author: OP Choudhary; Email: dr.om.choudhary@gmail.com

Received: 19 June, 2018

Revised: 05 Sept., 2018

Accepted: 09 Sept., 2018

ABSTRACT

The present study has been carried out on the mandible of Zovawk. The mandible was the largest and heaviest bone of the skull. The mandibular symphysis was fully ossified forming an immovable joint. The mandible of Zovawk carried 6 incisor, 2 canines, 8 premolars and 6 molars. The caudal articular extremity on dorsal surface presented condylar process and coronoid process with the intervening mandibular notch. The mandibular tuberosity was not recorded in the present study. The coronoid process curved caudally and extended caudo-dorsally above the condyle to form the highest point of the mandible. The mandibular foramen was large, which marked the entrance into mandibular canal which traversed laterally on the mandible and opened in the mental foramen at the level below the lower cheek teeth. The length and height of the mandible were 25.02±0.09 cm and 10.54±0.07 cm, respectively in Zovawk.

Keywords: Mandible, Zovawk, Morphological, Mental foramen

Piggery plays an important role in the rural economy of North East (NE) India. Among all the livestock, pig is one of the most valued and popular as almost 100% tribal population in the region are pork eaters (Mayengbam *et al.*, 2014). North eastern region has the highest population and concentration of pig per household than any other state or region of the country. The total pig population of Mizoram is around 1,17,675 (Livestock census, 2012) whereas the Zovawk population of Mizoram is about 43,000 (Livestock census, 2012). Zovawk is newly identified breed of pig of Mizoram approved by breed registration committee of Indian Council of Agricultural Research (ICAR), New Delhi (Choudhary, 2018). The aim of this work is to investigate mandible of local Mizo pig, thereby making a contribution in filling the gap of knowledge in the field of anatomy.

The present study was conducted on the mandible of ten adult Zovawk of either sex. The present study was conducted on the mandible of ten Zovawk pigs of either sex. The samples for the study were collected from local slaughter houses near to the college campus. The collected

samples of the Zovawk pig were macerated using the standard maceration technique (Choudhary *et al.*, 2015 a,b). The photographs of the skull of Zovawk were taken by the Nikon D3200 digital SLR camera and labeled with Adobe Photoshop 7 and CS6 extended version 13.0.1. The length and height of the mandible were measured and subjected to routine statistical analysis (Snedecor and Cochran, 1994).

The mandible (Fig. 1, 2) was the largest and heaviest bone of the skull as also reported in ox (Raghavan, 1964) and horse (Getty, 1975). The mandibular symphysis of Zovawk was fully ossified (Fig. 2) forming an immovable joint as also reported in horse (Getty, 1975); however the mandibular symphysis was not fully ossified in ox (Raghavan, 1964), dog (Miller *et al.*, 1964), chital (Kumawat *et al.*, 2014) and blackbuck (Choudhary *et al.*, 2015).

The mandible of Zovawk carried 6 incisor, 2 canines, 8 premolars and 6 molars (I3, C1, PM4, M3 × 2) as shown in Fig. 2.

The mandibular tuberosity was not recorded in the present study as also reported in leopard (Kalita *et al.*, 2001),

horse (Getty, 1975), ox (Raghavan, 1964), dog (Miller *et al.*, 1964), tiger (Joshi, 2004), chital (Kumawat *et al.*, 2014) and blackbuck (Choudhary *et al.*, 2015). However, the mandibular tuberosity was in the form of a tubercle in camel but it was well developed in yak (Archana *et al.*, 1998).

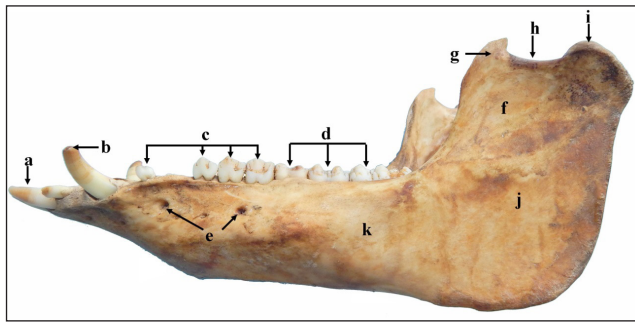


Fig. 1: Lateral view of the mandible of Zovawk showing incisor (a), canine (b), premolars (c), molars (d), mental foramina (e), fossa (f), coronoid process (g), mandibular notch (h), coronoid process (i), ramus (j) and (k) body.




Fig. 2: Dorsal view of the mandible of Zovawk showing ossification (a), coronoid process (b), mandibular foramen (c), condylar process (d), incisor (I), canine (C), premolar (PM) and molar teeth (M).

The horizontal part of ramus of the Zovawk mandible was slightly curved dorso-ventrally with its convexity facing ventral and did not touch the surface at both ends when kept on a flat surface. The incisive parts of the body remained lifted from the ground as also reported in ox (Raghavan, 1964) and blackbuck (Choudhary *et al.*, 2015); whereas incisive parts of the body of the mandible was straight in tiger (Joshi, 2004).

The ventral border of ramus was convex in its length as also described in dog (Miller *et al.*, 1964), ox (Raghavan, 1964), yak (Archana *et al.*, 1998) and chital (Kumawat *et al.*, 2014) and blackbuck (Choudhary *et al.*, 2015); whereas it was thick, straight and slightly rounded in tiger (Joshi, 2004), rounded and nearly straight in young horses and narrower and sharp in older horses (Getty, 1975).

The alveolar border was straight in Zovawk, however the alveolar border slightly concave in leopard (Kalita *et al.*, 2001) and blackbuck (Choudhary *et al.*, 2015).

The lateral surface of ramus dorsally presents a fossa, however the fossa was big, triangular in tiger (Joshi, 2004), concave and roughened in camel (Singh, 1984).

The caudal articular extremity on dorsal surface presented condylar process and coronoid process with the intervening mandibular notch as also reported in ox (Raghavan, 1964), yak (Archana *et al.*, 1998), leopard (Kalita *et al.*, 2001), chital (Kumawat *et al.*, 2014) and blackbuck (Choudhary *et al.*, 2015).

The coronoid process curved caudally and extended caudo-dorsally above the condyle to form the highest point of the mandible as also reported in leopard (Kalita *et al.*, loc. cit), yak (Archana *et al.*, 1998) and blackbuck (Choudhary *et al.*, 2015). The head of the condylar process was elongated transversely as also reported in ox (Raghavan, 1964) and tiger (Joshi, 2004).

The mandibular foramen was large, which marked the entrance into mandibular canal which traversed laterally on the mandible and opened in the mental foramen at the level below the lower cheek teeth (Fig. 3). The mental foramina were two in the present study as also reported in leopard (Kalita *et al.*, 2001), however, the mental foramen was single in the present study as also reported in horse (Getty, 1975), ox (Raghavan, 1964), yak (Archana *et al.*, 1998), chital (Kumawat *et al.*, 2014) and blackbuck (Choudhary *et al.*, 2015).

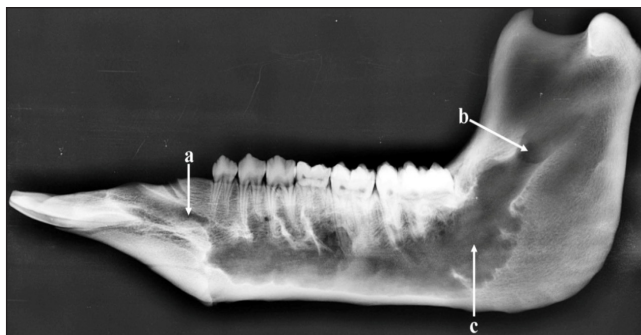


Fig. 3: Radiograph of the mandible (lateral view) of Zovawk showing mental foramen (a), mandibular foramen (b) and mandibular canal (c).

The length and height of the mandible were 25.02 ± 0.09 cm and 10.54 ± 0.07 cm, respectively in Zovawk, however the length and height of the mandible were 12.00 ± 1.89 cm and 6.90 ± 1.09 cm in west African dwarfs goats of Nigeria (Olopade and Onwuka, 2005), 27.4 cm and 15.88 cm in Iranian native cattle (Monfared, 2013b); 39.9 cm and 9.92 cm in Iranian one-humped camels (Monfared, 2013a); 16.53 ± 0.128 cm and 10.69 ± 0.024 cm in blackbuck (Choudhary and Singh, 2015a,b); 42.98 ± 0.624 cm and 22.58 ± 0.287 cm, respectively in dromedary camel (Choudhary *et al.*, 2016) and 33.25 ± 0.30 cm and 16.88 ± 0.124 cm in Indian wild pig (Choudhary *et al.*, 2017).

CONCLUSION

Our concluded that the mandible of Zovawk was largest and heaviest bone of the skull with ossified mandibular symphysis but the mandibular symphysis was not ossified in the ruminants. The mental foramen was two in our but same foramen was single in other domestic animals.

CONFLICT INTEREST

The authors have declared no potential conflicts of interest with respect to the research, authorship, and / or publication of the article.

ACKNOWLEDGMENTS

The financial support and facilities provided by the Central Agricultural University, Imphal, India is duly acknowledged. The authors are thankful to the Dean,

College of Veterinary Sciences and Animal Husbandry, Central Agricultural University, Aizawl, Mizoram for providing all the necessary facilities to carry out research work.

REFERENCES

- Archana, Sudhakar, L.S. and Sharma, D.N. 1998. Anatomy of the mandible of yak (*Bos grunniens*). *Indian J. Vet. Anat.*, **10**(1/2):16-20.
- Choudhary, O.P. (2018). Applied Anatomy of the Head Region of Local Mizo Pig (Zovawk) and Its Clinical Implications during Regional Anesthesia. IRP Report submitted to the Central Agricultural University, Imphal, Manipur, pp. 6-18.
- Choudhary, O.P. and Singh, I. 2015a. Applied anatomy of the maxillofacial and mandibular regions of the Indian blackbuck (*Antelope cervicapra*). *J. Anim. Res.*, **5**(3): 497-500.
- Choudhary, O.P. and Singh, I. 2015b. Morphometrical studies on the skull of Indian blackbuck (*Antelope cervicapra*). *Int. J. Morphol.*, **33**(3): 868-876.
- Choudhary, O.P., Kalita, P.C., Kalita, A. and Doley, P.J. 2016. Applied anatomy of the maxillofacial and mandibular regions of the dromedary camel (*Camelus dromedarius*). *J. Camel Prac. Res.*, **23**(1): 127-131.
- Choudhary, O.P., Kalita, P.C., Kalita, A. and Doley, P.J. 2017. Applied anatomy of the head region of the Indian wild pig (*Sus scrofa*) and its clinical value during regional anesthesia. *J. Anim. Res.*, **7**(2): 339-344.
- Choudhary, O.P., Singh, I., Bharti, S.K., Khan, I.M., Sathapathy, S. and Mrigesh, M. 2015a. Gross and morphometrical studies on mandible of blackbuck (*Antelope cervicapra*). *Int. J. Morphol.*, **33**(2): 428-432.
- Choudhary, O.P., Singh, I., Bharti, S.K., Mohd, K.I., Dhote, B.S. and Mrigesh, M. 2015b. Clinical anatomy of head region of Indian blackbuck. *Indian Vet. J.*, **92**(3): 59-63.
- Getty, R. 1975. *The Anatomy of the Domestic Animals*. Vol. I, 5th edn. W.B. Saunder's Company, Philadelphia.
- Joshi, H. 2004. Gross anatomical studies of the skull of Indian tiger (*Panthera tigris*). M.V.Sc. Thesis submitted to the Rajasthan Agriculture University, Bikaner.
- Kalita, A., Sarma, M. and Sharma, K.K. 2001. Anatomy of mandible of Indian Leopard. *Indian Vet. J.*, **12**(78): 1138-1140.
- Kataba, A., Mwaanga, E.S., Simukoko, H. and Parés, C.P.M. 2014. Clinical anatomy of the head Region of Gwembe Valley dwarf goat in Zambia. *Int. J. Vet. Sci.*, **3**(3): 142-146.
- Kumawat, R., Mathur, R., Joshi, S. and Choudhary, O.P. 2014. Gross morphological studies on mandible of Indian blackbuck (*Axis axis*). *Ind. Vet. J.*, **91**(9): 105-107.



- Mayengbam, P., Tolenkhomba, T.C., Ali, M.A., Saikia, P., Singh, N.S. and Hmar, L. 2014. Electrolyte (Na, K, Cl, Ca, Pi and Mg) profile of Zovawk pigs of Mizoram, India in different age groups. *Int. Multidisciplinary Res. J.*, **2**(2): 49-51.
- Miller, M.E., Christensen, G.C. and Evans, H.E. 1964. *Anatomy of the Dog*. W.B. Saunder's Company, Philadelphia.
- Monfared, A.L. 2013a. Gross anatomical measurements of the head region of the Iranian native cattle (*Bos taurus*) and Their Clinical Value for Regional Anesthesia. *Global Vet.*, **10**(2): 219-222.
- Monfared, A.L. 2013b. Applied anatomy of the head regions of the one-humped camel (*Camelus dromedarius*) and its clinical implications during regional anesthesia. *Global Vet.*, **10**(3): 322-326.
- Olopade, J.O. and Onwuka, S.K. 2005. Some aspects of the clinical anatomy of the mandibular and maxillofacial regions of the west African dwarf goat in Nigeria. *Int. J. Morphol.*, **23**(1): 33-36.
- Raghavan, D. 1964. *Anatomy of ox*. Indian Council of Agricultural Research, New Delhi.
- Singh, P. 1984. Gross anatomical studies on the skull of camel (*Camelus dromedarius*). Thesis M.V.Sc. Haryana Agriculture University, Hisar.
- Snedecor, G.W. and Cochran, W.G. 1994. *Statistical Methods*. 8th edn. Iowa State University Press, Ames, Iowa, USA.