



## **Surgical Resection of Multiple Vaginal Fibrosarcoma in an Intact Female Dog**

Naveen Kumar Verma<sup>1\*</sup>, Rohit Singh<sup>2</sup>, Mamta Pathak<sup>2</sup>, Aditya Agrawal<sup>3</sup>,  
Shailesh Kumar Patel<sup>2</sup>, Aakanksha<sup>1</sup> and Alok Singh<sup>2</sup>

<sup>1</sup>Division of Surgery, ICAR-IVRI, Izatnagar, Bareilly-243122, Uttar Pradesh, India

<sup>2</sup>Division of Pathology, ICAR-IVRI, Izatnagar, Bareilly-243122, Uttar Pradesh, India

<sup>3</sup>Division of Animal Biochemistry, ICAR-IVRI, Izatnagar, Bareilly-243122, Uttar Pradesh, India

\*Corresponding author: dr.naveenvermavet07@gmail.com

### **ABSTRACT**

An eight-year-old Labrador retriever bitch weighing 30 kg with history of sanguineous vaginal discharge associated with progressive perineal enlargement for last 1 year was presented to the Referral Veterinary Polyclinics of Indian Veterinary Research Institute, Izatnagar, Bareilly. Clinical examination revealed multiple palpable growths of varied size in the vaginal canal. Surgical resection of the same was performed under diazepam-ketamine anesthesia. On the basis of histopathological examination, the removed growth was diagnosed as Fibrosarcoma. The animal recovered uneventfully with no post-operative complications and reoccurrence till one month after surgery.

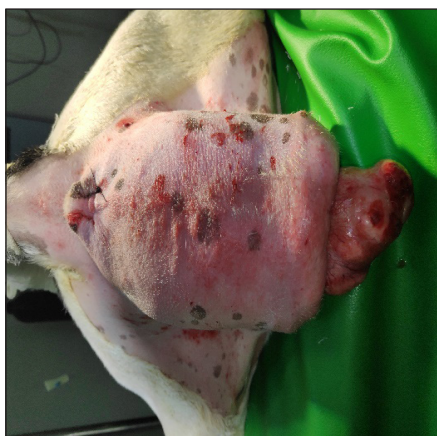**Keywords:** Cystic ovaries, Vaginal Fibrosarcoma, Episiotomy

Vaginal tumors are usually occurs in older bitches and are the second most common reproductive *tumour in dogs*, comprising 2.4-3 percent of *all canine tumors*. Most commonly, tumors of the reproductive organ like leiomyosarcomas, fibroleiomyomas, lipomas and squamous cell carcinomas has been reported in intact females (Fossum, 2013). Among them, leiomyomas originating from the mesenchymal tissue are most commonly observed in bitches with the age group of five to sixteen (Brodey and Roszel, 1967). Leiomyomas are slow growing, non-invasive, nonmetastatic, smooth muscle masses that rarely cause any specific clinical signs (Klein, 2001). Within the reproductive tract, it occurs more frequently with a rate of 8:1 in vagina/vulva and uterus respectively (Brodey and Roszel, 1967). Tumours of the reproductive tract in the bitch are frequently associated with estrogen secreting tumors or ovarian follicular

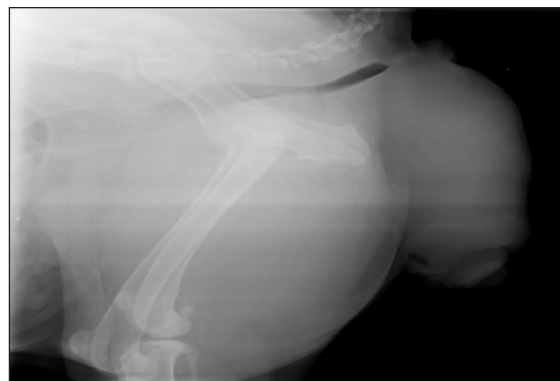
cysts. Concurrently, cystic endometrial hyperplasia, mammary hyperplasia and/or neoplasia may also be associated with it (Miller *et al.* 2003). Previously, vaginal neoplasms in intact female dogs were reported but paucity of reports regarding vaginal fibrosarcoma with cystic ovaries has been observed (Mumba *et al.* 2013; Kumar *et al.* 2014). The growths may or may not be pedunculated and can grow in concentric way either towards cervix or exterior (Al-Kenanny *et al.* 2013). This may cause obstruction to urethra and rectum extra luminally or intra luminally (Gupta *et al.* 2014). Surgery may include either episiotomy and mass excision or more aggressive procedures such as vaginectomy, urethroplasty, and ventral pelvic osteotomy (Salomon *et al.* 2004). The present case reports successful surgical management of vaginal fibrosarcoma developed in a female Labrador dog that also had cystic ovaries.

## MATERIALS AND METHODS

A 08-year-old Labrador retriever bitch weighing 30 kg with the history of sanguineous vaginal discharge with progressive perineal enlargement, tenesmus, decreased appetite, and lethargy for last 01 year was presented to the Referral Veterinary Polyclinics of Indian Veterinary Research Institute. On physical examination, the dog was quiet but alert and responsive. Clinical examination revealed normal heart rate, respiratory rate, rectal temperature and a general body condition. External digital palpation of the perineal region revealed large, firm and non-painful vaginal masses protruding through the vulva (Fig.1). Moreover, the per-vaginal examination confirmed the presence of multiple large, hard, solid, encapsulated masses in the vestibule, vagina up to the level of cervix. Initial diagnostic tests included complete blood cell count, serum biochemical analysis, thoracic and abdominal radiographs and ultrasound of abdomen and vagina. Lateral thoracic radiography was performed in order to rule out lung metastasis, and no pathological images were found in both thoracic and abdominal radiograph. However, circumscribed swellings having soft tissue opacity in the perineal region was observed in lateral abdominal radiograph (Fig. 2). Ultrasonography of the vaginal mass revealed a moderately vascular space occupying echogenic masses.



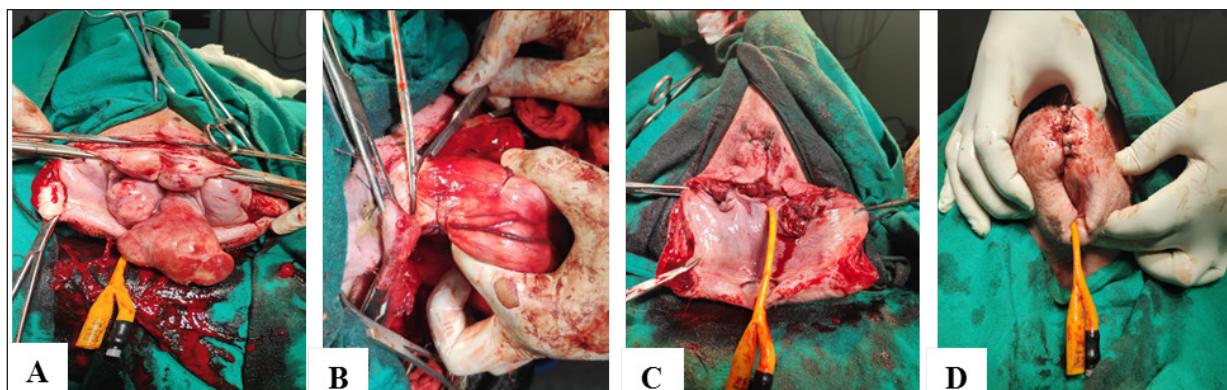
**Fig. 1:** Pre-operative image showing perineal swelling and vaginal deformation



**Fig. 2:** Radiographic image of the vaginal growths

Abdominal ultrasonography showed the presence of both left and right ovaries, uterus of normal size, but two large anechoic spherical structure of about 02 cm and 1.5 cm in diameter were located on the surface of both the ovaries. On the basis of clinical examination and different diagnostic tests it was diagnosed as a case of vaginal tumour with cystic ovaries.

The dog was prepared for aseptic surgery and premedicated with atropine (0.04 mg/kg SC) and five minutes later anaesthesia was induced by diazepam (0.5 mg/kg IV) and ketamine (5 mg/kg IV), followed by endotracheal intubation. Anaesthesia was maintained with diazepam-ketamine combination (1:1) administered intravenously. An episiotomy was performed to approach the vaginal growths. The masses in the perineal region were found to be smooth, irregular shape growths and their size ranged between peanut to big lemon size. The masses were firm to touch and had non-defined stalks attached to the vestibule, vaginal walls and cervix (Fig. 3A). As the urethral orifice was very close to the pedicle of the mass, a Foley's catheter of 10 french size was placed in the urethra to help in defining and avoiding trauma to this structure. The pedicles of the masses were ligated and transfixed then transected from base close to the urethra (Fig. 3B) and the remaining growths at the level of cervix, vagina and vestibule were excised by applying ligatures with polyglactin-910 No. 1-0. After complete resection of the mass a portion of it



**Fig. 3:** (A) Intraoperative image showing tumour masses after episiotomy; (B&C) Intraoperative image showing ligation, resection and reconstruction of defect; (D) Episiotomy site closure and vaginal reconstruction

was sent for histopathological examination. The excision site was closed by approximating the mucosa of vaginal floor and submucosal dead space was occluded by simple continuous suture pattern using polyglactin-910 No.1-0 (Fig. 3C) and skin was sutured by simple interrupted suture pattern using polyamide No. 1 to provide good aesthetic look to the surgical site (Fig. 3D). Postoperative treatment involved Injection Ceftriaxone, Meloxicam and tablet Serratiopeptidase and Rabepazole for five consecutive days. Daily antiseptic dressing with Betadine (5% povidone iodine) and bandaging on alternate days was advised.

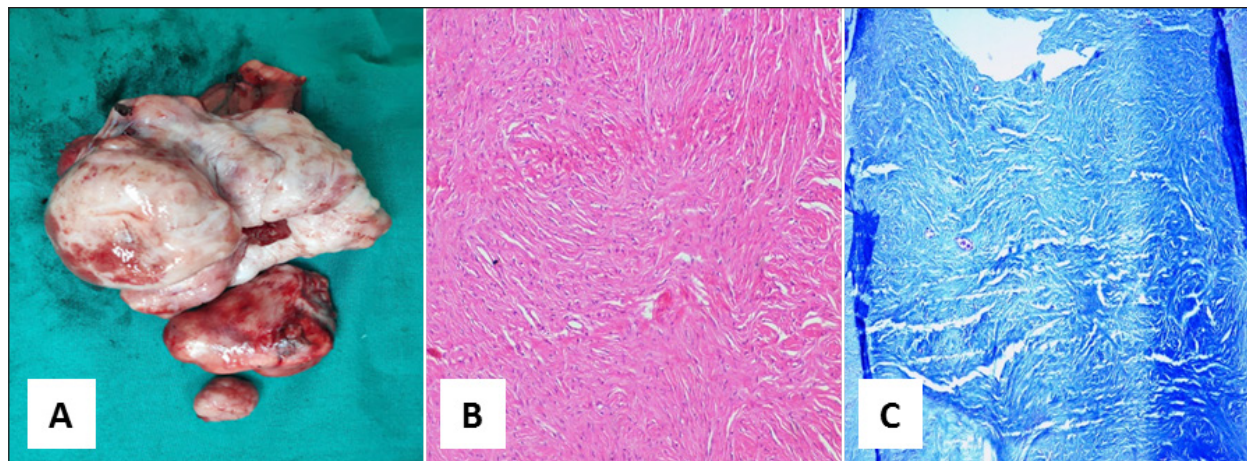
### RESULTS AND DISCUSSION

The bitch made an uneventful recovery from anaesthesia with no postoperative complications such as urine retention or incontinence. Sutures were removed on the 12<sup>th</sup> post-operative day after complete healing of the wound. The most common types of tumors found in the genital tract of bitches include benign, smooth muscle tumors of the vagina and vulva. These tumors are variably referred to as leiomyomas, fibroleiomyomas, fibromas and polyps depending on the amount of connective tissue present (MacLachlan and Kennedy, 2002). Among these, fibrosarcomas are relatively unusual vaginal tumours in bitches and of mesenchymal origin (Neelu and Tiwari,

2009). These growths mostly seen from outside and may have concealed presence in vagina and leads to extra luminal obstruction of urethra and rectum as observed in the present case (Gupta *et al.* 2014). The confirmed diagnosis of vaginal leiomyomas can be done by histopathology. In animals, aetiology of vaginal tumours is not fully understood but some studies suggest that hormones have an influence on their occurrence (Miller *et al.* 2003). Brodey and Roszel, (1967) reported that incidence was highest between 5 to 16 years of age.

Treatment of vaginal leiomyomas is primarily surgical excision (Klein, 2001) and sometimes episiotomy may require for large tumours as in the present case (Rollon *et al.* 2008) but the condition can recur under the influence of hormones (Miettinen and Fetsch, 2006). Therefore, ovariectomy is advised to prevent reoccurrence. In the present case ultrasonography revealed cystic ovaries which further supports hormonal influence for oncogenesis. Complications such as iatrogenic damage to the urethra or accidental injury to other perineal structures can occur during resection of vaginal mass while urine retention, incontinence and urethral obstruction may be noticed after resection. However, the present case did not show any of the postoperative complications or reoccurrence of vaginal tumour till one month after the surgery.





**Fig. 4:** (A) Excised tumour masses of varying size; (B) Photomicrograph showing proliferation of spindle shaped cells (fibroblasts) arranged haphazardly and frequently forming whorl-like pattern. H&E x100; (C) Photomicrograph showing blue stained collagen deposits in the matrix and fibroblasts. Masson's trichrome x100.

On gross examination, multiple encapsulated vaginal mass revealed irregular growths ranged between peanut to big lemon size having pinkish appearance and firm consistency (Fig. 4A). Histopathological examination revealed proliferation of spindle shaped cells (fibroblasts) arranged haphazardly and frequently forming whorl-like pattern. The nuclei of proliferating cells were hyper chromatic and elongated to oval in shape. The cytoplasm was scanty and nucleoli were not visible. Cells were arranged in interwoven pattern with marked pleomorphism indicating malignancy; hence the mass was diagnosed as vaginal fibrosarcoma (Fig. 4B). Furthermore, the Masson's trichrome stained sections revealed blue coloured collagen indicating the tumour as fibrous in origin (Fig. 4C).

#### CONCLUSION

Vaginal fibrosarcoma developed in the present case was successfully managed through episiotomy and ovariohysterectomy procedure. Therefore, it may be suggested that ovariohysterectomy is crucial in the prevention of the genital tumours in female dogs.

#### REFERENCES

- Al-Kenanny, E.R., Al-Hayani, O.H. and Al-Annaz, M.Th. 2013. Vaginal fibrosarcoma in a bitch: a case report. *Iraqi. J. Vet. Sci.*, **27**(2): 119-121.
- Brodey, R.S. and Roszel, J.F. 1967. Neoplasms of the canine uterus, vagina, and vulva: a clinicopathologic survey of 90 cases. *J. Am. Vet. Med. Assoc.*, **151**(10): 1294.
- Fossum, T.W. 2013. Surgery of the Genital and Reproductive systems, in *Small Animal Surgery*, In Fossum TW (eds.) 4<sup>th</sup> Edn, Elsevier Mosby, Philadelphia, pp. 825.
- Gupta, P., Gupta, A.K., Kushwaha, R.B., Dwivedi, D.K. and Sharma, A. 2014. Urethral and Rectal Obstruction Caused by Vaginal Tumour in a Bitch. *Ind. Vet. J.*, **91**(04): 79-80.
- Klein, M.K. 2001. Tumours of the female reproductive system. In: Withrow SJ and MacEwen EG (editors), *Small Animal Oncology*. WB Saunders, Philadelphia, USA. **1**(1): 445-454.
- Kumar, R.V.S., Kamalakar, G., Mahesh, R., Sumiran, N., Devaratnam, J. and Kumar, A.A. 2014. Surgical Management of a Rare Case of Extensive Obstructive Fibrosarcoma in a Pomeranian Bitch. *Res. J. Vet. Pract.*, **2**(6): 108-110.
- MacLachlan, N.J. and Kennedy, P.C. 2002. Tumors of the genital system. In: D.J. Meuten (ed.), *Tumors in domestic animals*, 4<sup>th</sup> ed., Iowa State University Press, Ames, IA, pp. 547-573.

- Miettinen, M. and Fetsch, J.F. 2006. Evaluation of biological potential of smooth muscle tumors: Review. *Histopathology*, **48**(1): 97.
- Miller, M.A., RamosVara, J.A., Dickerson, M.F., Johnson, G.C., Pace, L.W., Kreeger, J.M., Turnquist, S.E. and Turk, J.R. 2003. Uterine neoplasia in 13 cats. *J. Vet. Diagn. Invest.*, **15**: 575-522.
- Mumba, C., Pandey, G.S., Chijikwa, J. and Munjita, S. 2013. Multiple vaginal fibrosarcoma in a Dog. *Ind. Vet. J.*, **90**(2): 108-109.
- Neelu, G. and Tiwari, S.K. 2009. Study on incidence, histopathological features and surgical managements of neoplasms in canines. *Vet. World*, **2**(10): 393-395.
- Rollon, E., Millan, Y., Martin, J. and Mulas, D.L. 2008. Effects of aglepristone, a progesterone receptor antagonist in a dog with a vaginal fibroma. *J. Small. Anim. Pract.*, **49**: 41-43.
- Salomon, J.F., Deneuche, A. and Viguier, E. 2004. Vaginectomy and urethroplasty as a treatment for non-pedunculated vaginal tumours in four bitches. *J. Small. Anim. Pract.*, **45**(3): 157-161.

