

Ultrasonographic and Clinical Studies on Benign Prostatic Hyperplasia in Dogs

K. Rajkumar* and C. Ansarkamran

Department of Veterinary Medicine, Veterinary College, KVAFSU, Hebbal, Bangalore, India

*Corresponding author: rajvet10@gmail.com

Abstract

Benign prostatic hyperplasia (BPH) is prostate gland enlargement in which squamous metaplasia or glandular hyperplasia, or together, result from hormone imbalance in intact male dogs. Seventy five clinical cases of different ages and breeds, presented to ultrasonographic unit Veterinary college hospital, Hebbal, Bengaluru were utilized for the present investigation. The most common clinical findings in BPH were urinary retention, constipation, dysuria, cystitis, and haematuria. Clinical signs were evident in six dogs and in three dogs BPH was an incidental finding. Ultrasonography examination revealed enlarged prostate with normal to increased echogenicity, and with homogeneous or inhomogeneous echotexture. On transverse image, the two lobes were usually symmetrical. Benign prostatic hyperplasia with intraprostatic cysts was observed in two dogs one in mongrel and the other boxer aged 9 and 8 years respectively. Studies towards early diagnosis of this condition are crucial for effective treatment and improvement of quality of life of affected animals.

Keywords: Benign prostatic hyperplasia, Ultrasonography, Squamous metaplasia, Glandular hyperplasia, dogs

Benign prostatic hyperplasia (BPH) is prostate gland enlargement in which squamous metaplasia or glandular hyperplasia, or together, result from hormone imbalance in intact male dogs (Ladds, 1993). It is usually a disease of older dogs which occurs more than 4 years, and can be reflected in variation of normal physiologic manifestations in dogs. Prostatic hyperplasia is often an accompanying finding on physical examination, but significant enlargement can lead to signs affecting urination or defecation. In few cases, it may lead to clinical signs that are more frequently associated with prostatitis or neoplasia, such as bloody urethral discharge (Kustritz and Merkel, 1998). Due to the increasing interest of owners to obtain precious offspring, male genital tract's

pathology is of specific importance, and the prostate is an significant and vital part of the pathology of male genitalia. Benign prostatic hyperplasia (BPH) describes age-dependent changes of cell size (hypertrophy) and cell number (hyperplasia) frequently combined with the development of small intraprostatic cysts.

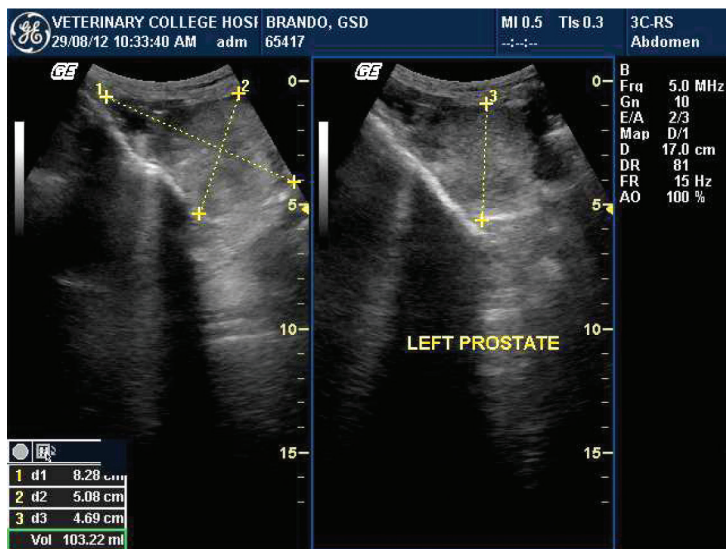


Fig. 1: Benign prostatic hyperplasia in 11 year old German Shepard. Sagittal and transverse image of the prostate which is enlarged, inhomogeneous, with an irregular contour and mixed echogenicity

The underlying factors for development of BHP are androgen and most likely oestrogen. Dogs affected by BPH show problems in urination (tenesmus, dysuria) and defecation. Further BPH and prostatic cysts may also predispose for prostatitis and abscess development (Goericke and Hoffmann, 2008). The frequently used methods to diagnose canine prostate gland disease are rectal examination and abdominal ultrasound. The aim of this study was to investigate the prevalence of BPH and its clinical manifestation.

Materials and Methods

Seventy five clinical cases of different ages and breeds, presented to ultrasonographic unit Veterinary college hospital, Hebbal, Bengaluru were utilized for the present investigation. The ultrasonographic examination was done using a 6 to 10 MHz Curvilinear-Array Sector Doppler probe (GE Logic Book XP). The prostate was examined transabdominally after routine

clipping and application of contact gel. The dog was usually positioned in dorsal recumbency. Prostate is located in the caudal abdomen or cranial pelvic canal, it is identified caudal to the urinary bladder and ventral to the distal descending colon and rectum. Ultrasonographic examination is performed in transverse and sagittal plane.

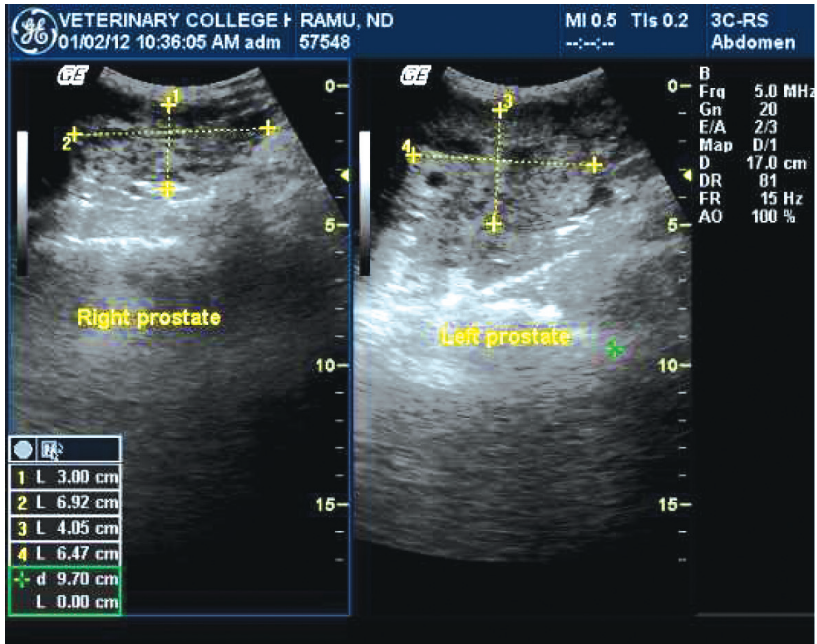


Fig. 2: Benign prostatic hyperplasia and intraprostatic cysts in a 9 year old mongrel dog. Sagittal image of the both prostate shows prostatic enlargement, inhomogeneity of the parenchyma, and multiple anechoic areas consistent with prostatic cysts

Results

Results revealed 9 out of 75 dogs with BPH. The most common clinical findings in BPH were urinary retention, constipation, dysuria, cystitis, and haematuria. Clinical signs were evident in six dogs and in three dogs BPH was an incidental finding. Ultrasonography examination revealed enlarged prostate with normal to increased echogenicity, and with homogeneous or inhomogeneous echotexture. On transverse image, the two lobes were usually symmetrical. Benign prostatic hyperplasia with intraprostatic cysts was observed in two dogs one in mongrel and the other boxer aged 9 and 8 years respectively. Solcan *et al.* (2007) also reported similar findings.

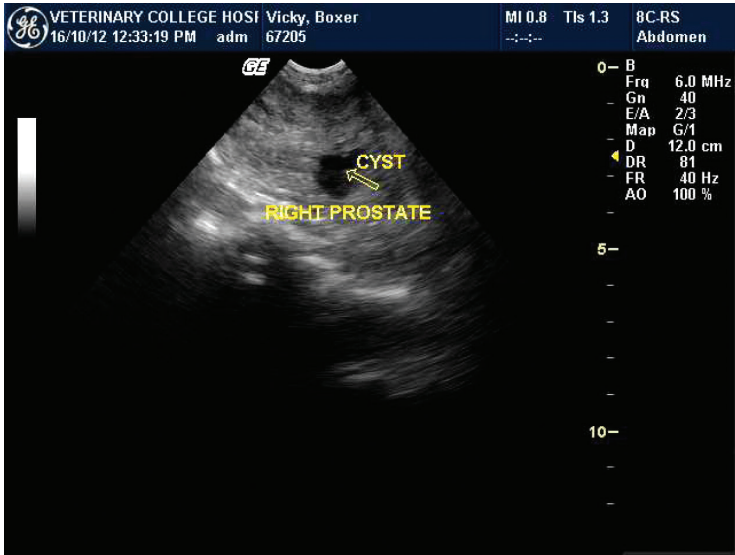


Fig. 3: Benign prostatic hyperplasia and intraprostatic cysts in 8 year old Boxer dog. Sagittal image of the both prostate shows prostatic enlargement, inhomogeneity of the parenchyma, and single anechoic areas consistent with prostatic cysts

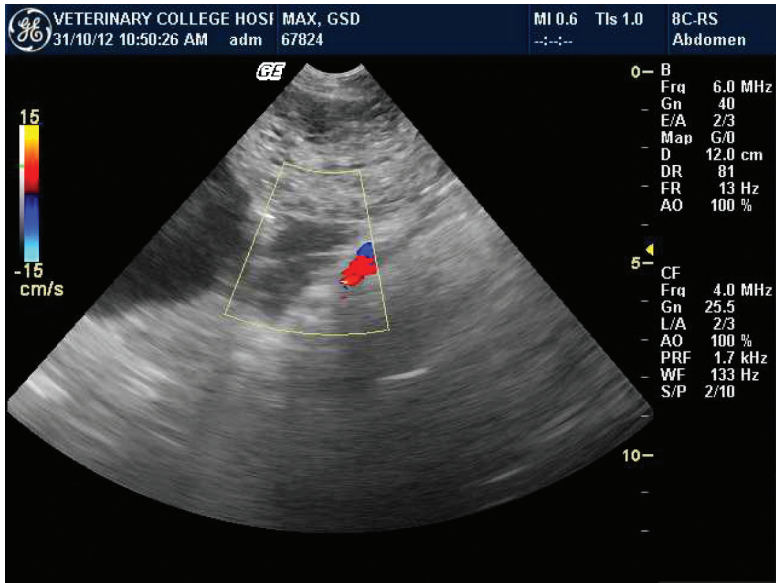


Fig. 4: Benign prostatic hyperplasia in 11 year old German Shepard. Sagittal image of the prostate which is enlarged, inhomogeneous, with an irregular contour and mixed echogenicity. Colour Flow Doppler showing prostate blood flow

Discussion

In intact dogs, the prostate was of fine to medium coarse echotexture with smooth margins, homogeneous and medium echogenicity. (Mattoon and Nyland, 2002). On sagittal image, the shape was round to ovoid. On transverse image, the two prostatic lobes were symmetrical. The vertical raphe and prostatic urethra with surrounding urethralis muscle were normally visible as hypoechoic area between both lobes. The urethral structures may be related with edge shadowing on transverse planes, which should not be misinterpreted as a lesion. Location, size and appearance of the prostate vary with previous disease, age and status of animal (Feeney *et al.* 1989).

The ultrasonographic appearance of benign prostatic hyperplasia were subtle inhomogeneity of the parenchyma without obvious enlargement. Often, but not always, the prostate was enlarged, in severe cases four time normal size (Ladds, 1993). The enlargement was symmetrical or asymmetrical, smooth or nodular, distorting the margin of the gland. Diffuse enlargement cause loss of the normal bilobed appearance of the prostate and the margins of the gland was seen and differentiated for the surrounding tissues. The echogenicity of the gland varies and may be diffusely homogeneous and hypoechoic to hyperechoid, but some degree of inhomogeneity was noted in most cases. Parenchymal texture varies from smooth to coarse. Scattered hyperchoic foci, thought to be secondary to increased vascularity and fibrosis, was present.

Intraparenchymal cysts of varying size and number were present; these probably represent dilated acini and ducts secondary to hyperplasia. Pathologic changes resulting in a heterogeneous appearance can make the diagnosis of benign prostatic hypertrophy difficult; differential diagnosis includes inflammation, infection, and neoplasia. As a general consideration, the ultrasonographic changes are usually less severe with benign prostatic hyperplasia than with inflammatory or neoplastic conditions. Hyperplasia should not disrupt the capsule of the prostate gland, nor there evidence of sublumbar lymph node enlargement.

Conclusion

It is concluded that about 90% of older dogs suffer from BPH, preventive geriatric examination should always include examination of the prostate to find early indications of BPH or prostatic cysts hyperplasia (BPH) describes age-dependent changes in cell (Goericke and Hoffmann, 2008). Studies towards early diagnosis of this condition are crucial for effective treatment and improvement of quality of life of affected animals.

References

- Feeney, D.A., Johnston, G.R., Klausner, J.S. and Bell, F.J. 1989. Canine prostatic ultrasonography. *Semin Vet Med Surg (Small Anim)*, **4**: 44-57.
- Goericke-Pesch, S. and Hoffmann. 2008. Benign prostatic hyperplasia - etiology, clinic, diagnostics and therapy in the dog; a review. *Kleintierpraxis*, **53**(3): 178-186.
- Kustritz, M.Y. and Merkel, L. 1998. Theriogenology question of the month. Benign prostatic hypertrophy (BPH), prostatitis, and prostatic neoplasia. *J Am Vet Med Assoc*, **213**: 807-809.
- Ladds, P.W. 1993. The male genital system. In Jubb KVF, Kennedy PC, Palmer (eds): *Pathology of Domestic Animals*, 4th ed. Orlando, Fla: Academic Press, pp. 471-529.
- Mattoon, J.S. and Nyland, T.G. 2002. Prostate and testes. In : Nyland TG, Mattoon JS, eds. *Small Animal Diagnostic Ultrasound*. Philadelphia: WB Saunders, pp. 250-266.
- Solcan, G., Codreanu, M.D., Boghian, V., Hritcu, L.D., Chiriac, I.S.B. and Drugociu, D. 2007. Use of ultrasonography for diagnostic of some prostate gland disorders in dogs and therapy principles. *Lucrai-Stiintifice-Medicina-Veterinara,-Universitatea-de-Stiinte-Agricole-si-Medicina-Veterinara-"Ion-Ionescu-de-la-Brad"-Iasi*, **50**(9): 320-325.