

Dystocia due to Diprosopus Parapagus fetus and its Successful Delivery through C- Section in a Non-Descript Goat

K. Kavitha¹, G.Monica², T. Sarath^{2*}, T.A. Kannan², Cecilia Joseph³, N. Arunmozhi⁴ and S. Balasubramanian⁵

¹Department of Veterinary Gynecology and Obstetrics, Madras Veterinary College, Tamil Nadu Veterinary and Animal Sciences University, Chennai, India

²Department of Clinics, Madras Veterinary College, Tamil Nadu Veterinary and Animal Sciences University, Chennai, India

³Department of Veterinary Anatomy, Madras Veterinary College, Tamil Nadu Veterinary and Animal Sciences University, Chennai, India

⁴Department of Veterinary Gynecology and Obstetrics, Madras Veterinary College, Chennai, India

⁵Director, Directorate of Clinics, Tamil Nadu Veterinary and Animal Sciences University, Chennai, India

*Corresponding author: drsarathvet@gmail.com

ABSTRACT

The present paper reports the successful delivery of a dicephalus monster fetus through Caesarean section and the features of dicephalic fetus in non-descript goat as recorded.

Keywords: Congenital Defects, Diprosopus Parapagus, Doe, Dystocia, Caesarean Section

Congenital defects are structural or functional abnormalities which may affect on isolated portions of a body system or entire system, or parts of several systems and leads to dystocia at the time of parturition (Long, 2001). The congenital defects are induced by genetic or environmental factors including infectious diseases, viruses, drugs, poisonings, plants, mineral salts and vitamin deficiency (A, D, E), hormonal factors, and physical reasons or by their interactions (Mazzulo *et al.*, 2003). Although the exact mechanism is not clear, the most readily accepted theory is based on the embryonic fission and formation of two organizing centers (Machin, 1993).

Conjoined twins have been reported in farm animals such as sheep and cattle (Unver *et al.* 2007). Etiological information about the

congenital duplication anomalies is rarely available. Dicephalus is a kind of conjoined symmetrical twins described as an abnormality due to incomplete separation of heads resulting from twinning in humans and animals (Gulbahar *et al.* 2005). The incidence of these types of congenital defects is very exceptional and reported in sheep (Monfared, 2013), goats (Mukaratirwa and Sayi, 2006), Cattle (Salami, 2011) and buffalo (Shukla, 2011). The present study reported about a rare case of dicephalic conjoined anomaly in a non-descript goat fetus.

Case History and Clinical examination

A 4-year-old non-descript pregnant doe in its second parturition was referred to the Large Animal Obstetrical Unit of Madras Veterinary College Teaching Hospital with the history

of straining for past six hours but unable to deliver the fetus. Upon vaginal examination, it was found that the fetus was in anterior presentation, dorso-sacral position with extended forelimbs, and two palpable heads joined around the region of neck. The fetus was dead and confirmed to be a dicephalic dead fetus. Simple traction of the fetus was tried but failed and per vaginal delivery was ruled out. It was decided to perform Cesarean section to relieve a dead dicephalic malformed female fetus. The doe had previously given birth to normal twins and there was no history of other defects within the flock.

TREATMENT AND DISCUSSION

The doe was surgically prepared for left lower flank approach (Fig. 1) and the left lateral laparohysterectomy was performed under local inverted L-block and regional anaesthesia at lumbosacral nerve block using 2% Lignocaine HCL after restraining the animal in right lateral recumbence. An oblique incision around 10 cm in length was made on the skin few centimeters in front of the corresponding stifle fold followed by muscle and peritoneum and the uterus was exteriorized. A small incision around 5 cm in length was made on the gravid horn of uterus in the inter-caruncluar area and removed a full term double head dead fetus. The uterus was closed by double rows of Lambert suture pattern (Fig. 2) with 2-0 PGA (Ethicon®, Johnson and Johnson) and routine closure of peritoneum, abdominal muscles and skin were performed. A course of systemic antibiotic (500 mg C-Tax, Intas Pharmaceutical), non-steroidal anti-inflammatory drug (2ml Melonex®, Intas Pharmaceutical) and daily antiseptic dressing (Loraxene ointment, Indian Herbs) for 5 days was given and the doe had an uneventful recovery. Radiograph of the fetus was done for evaluation of skeletal system followed by dissection for gross anatomical studies (Fig. 3 and 4).

Anatomic and pathologic examinations were

performed for detecting anomalies in the dicephalic dead fetus. The dead fetus had a single body with duplicated symmetrical heads attached at the level of occipital region. Appendicular skeleton consisted of a pair of fore limbs and a pair of hind limbs. No abnormalities noticed in the joints of appendicular skeleton on gross and radiographic examination. With regard to axial skeleton, there was complete duplication of skull with fully developed brain in both the cranial cavities. Both the skull fused at the level of occipital condyle and continued as single thereafter (Fig. 3 and 4). Both brain showed fully developed cerebral hemispheres, cerebellum, pons and medulla oblongata. Both the brain stem continued and joined to form a single spinal cord at the level of first cervical vertebra (atlas).

The external thorax, abdomen and pelvis were normal. However, the fetus was having two fully developed separate heads with 2 pairs of eyes and two pairs of ears (Fig. 5). The lateral external ears normally developed whereas medial ears were smaller in size. Both the nostrils were normal and both the foreheads developed normally. The upper jaw was slightly shorter for the right side head when compared to the left side head, however, the lower jaw was slightly protruding in the right fetal head (Fig. 6). The cranial and nasal bones have developed normally in both heads and two tracheas were running separately and left trachea bifurcates into two at the cranial media sternum into small and large division (Fig. 7). The small division of left trachea goes to the right lung and large division goes to the left lung through the hiatus. Right trachea, before entering into the hiatus, divides into smaller and larger divisions (Fig. 8). The right lung larger than the left with normal lobulation and, receives special bronchus and right media sternal lobe was fused but epical lobe of left lung was absent (Fig. 9). Two separate esophagi run up to thoracic inlet and fused at the cranial media sternum as shown in Fig. 10. Neck muscles were developed bilaterally and supra spinous ligament was single at its origin

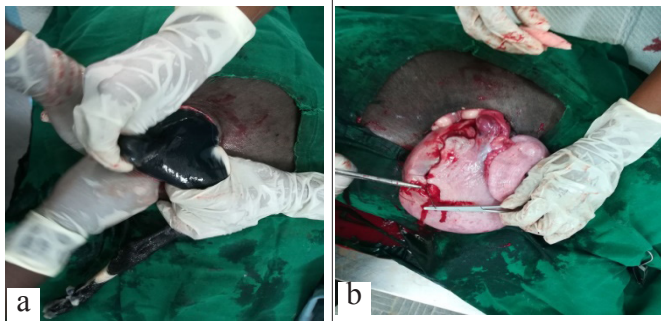


Fig. 1: Delivery of Diprosopus fetus through C – section by left flank approach (a) followed by suture of uterus (b)

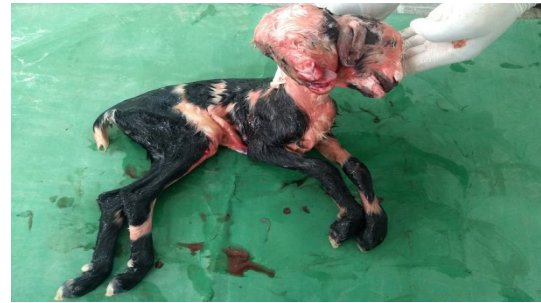

Fig. 2: Diprosopus parapagus dead fetus

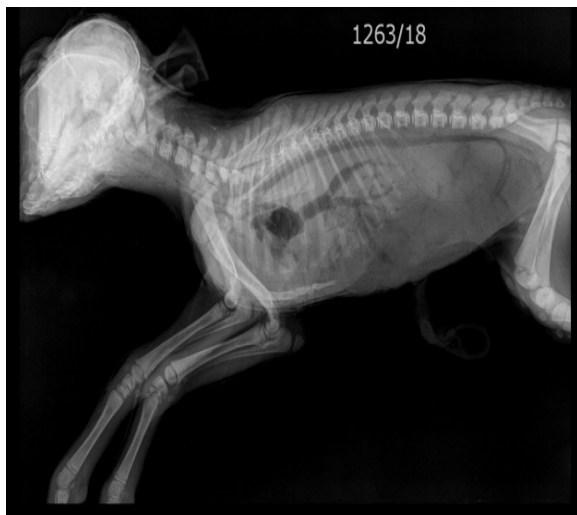

Fig. 3: X –ray showing Diprosopus parapagus with normal skeleton

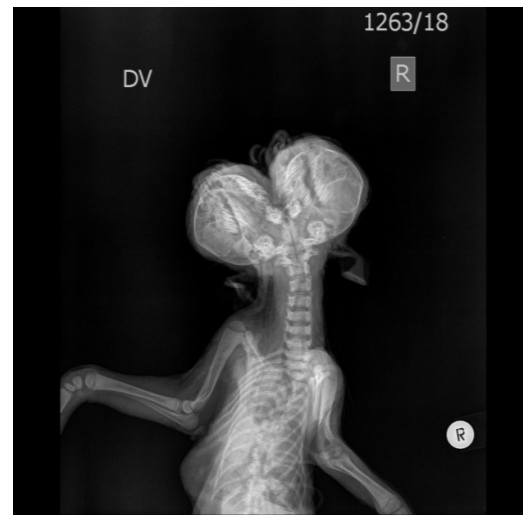

Fig. 4: X –ray showing Completely developed two separate heads

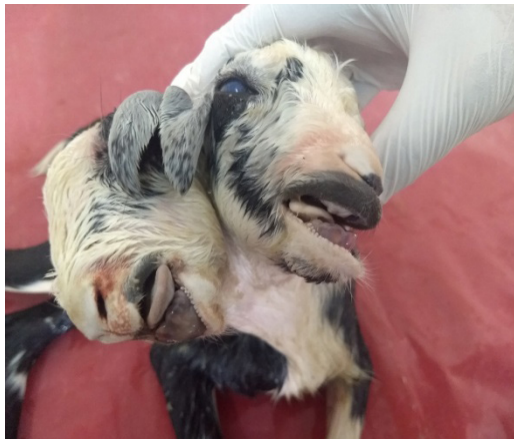

Fig. 5: The dicephalic fetal head is consists of two pairs of eyes and two pairs of ears

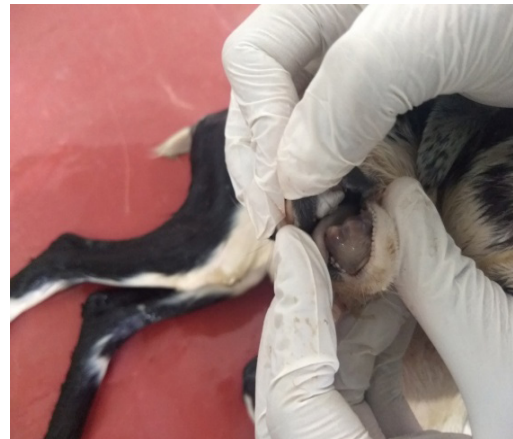

Fig. 6: Lower jaw was slightly protruding in the right fetal head

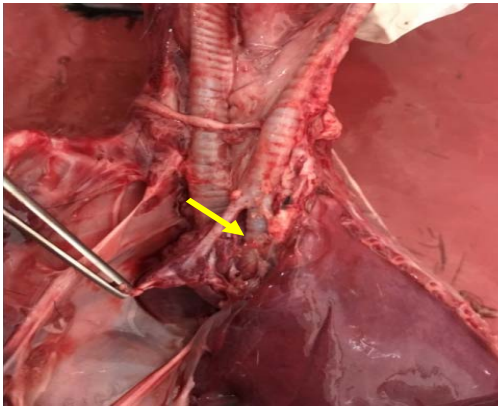


Fig. 7: Two tracheas running separately. Arrow showing left trachea bifurcating at the cranial media sternum into small and large divisions

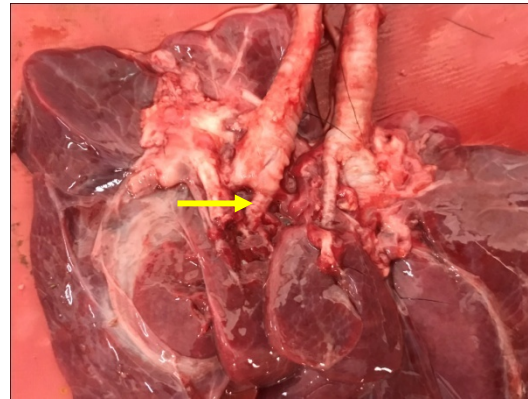


Fig. 8: Right trachea divides into smaller and larger divisions

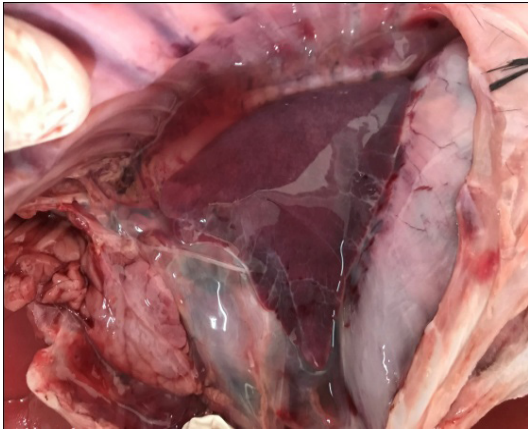


Fig. 9: Absence of left lung Epical lobe

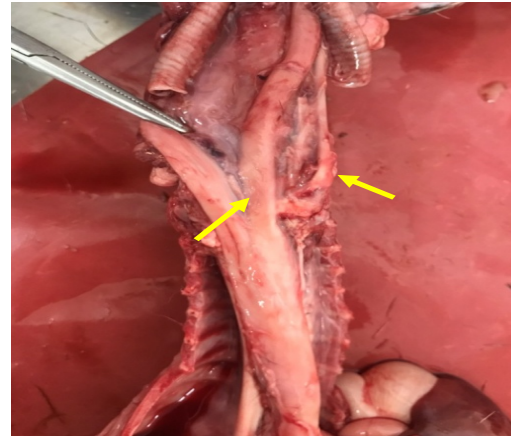


Fig. 10: Two separate esophagi fused at the cranial media sternum

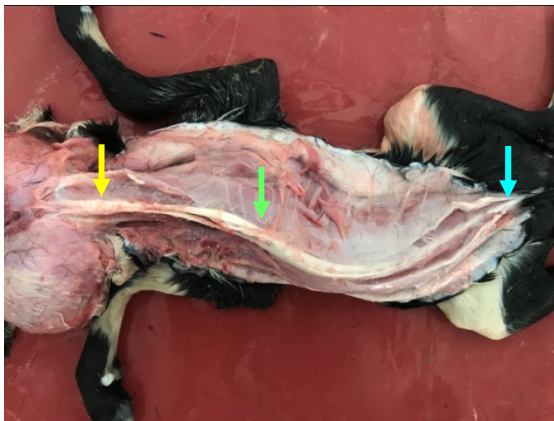


Fig. 11: Supraspinous ligament single at its origin (Blue arrow) which divides into two at the thoracolumbar region (Green arrow) and fused at the level of occipital (Yellow arrow)

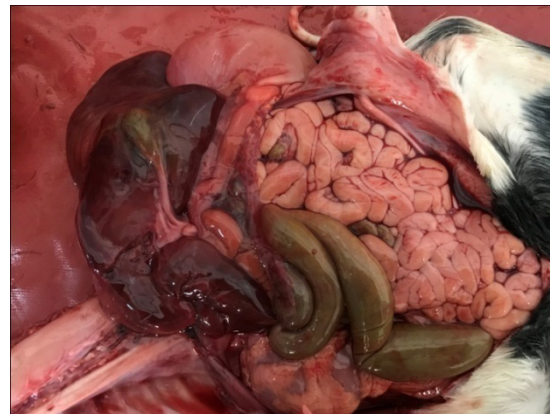


Fig. 12: Normal internal organs

and divides into two at the thoraco-lumbar region and continues as divided up to the head and fused at the level of occipital (Fig. 11). The internal organs like heart, liver, diaphragm, sternum, spleen, intestine and reproductive tract were found to be normal (Fig. 12).

All conjoined twins are monozygotic in origin and represent incomplete division of one embryo into two components, usually at some time during the primitive streak stage. Conjoined twins most frequently arise during primitive streak elongation or regression (Gulbahar *et al.* 2005) and result from a single embryonic disk that has undergone splitting between a single dorsal ward amniotic cavity and a single ventral ward yolk sac (Monfared *et al.* 2013). This is a rare disorder affecting 1:200 monozygotic twin pregnancies, 1:900 twin pregnancies and 1:25,000 to 1,00,000 births (Gungor *et al.* 2004). It is thought that conjoined twins are more common in cattle than in other domestic animals. The most severe ones among them may even cause premature death of the conceptus, abortion, mummification, and stillbirth. Less severe aberrations lead to varying degrees of structural abnormalities that may cause dystocia (Gungor, 2004). In conclusion, many conditions that are related to most of the congenital defects in human and animals have been reported. Teratogens include toxic plants, infectious agents, drugs, trace elements deficiencies, and physical agents such as radiation, hyperthermia, and embryo manipulations, which are in the scope of possible other factors that may cause this congenital defect (Dennis and Leipold, 1986). Since there is no recorded history about the dam and due to the inability to detect a causative agent, it is not possible to ascertain the cause of this anomaly. However, although it is not known if the duplication in this case is caused by genetic or environmental factors, genetic factors are suspected.

ACKNOWLEDGEMENTS

The authors acknowledges the Dean, Madras

Veterinary College and Director of Clinics, TANUVAS, Chennai, India for the facilities provided.

REFERENCES

- Long, S. 2001. Abnormal development of the conceptus and its consequences. In: Noakes DE, Parkinson TJ, England GCW, editors. *Arthur's veterinary reproduction and obstetrics*. 8th edition. W.B. Saunders, London, pp. 119–143.
- Mazzulo, G., Germana, A., De Vico, G. and Germana, G. 2003. Diprosopiasis in a lamb. A case report. *Anat. Histol. Embryol.*, **32**: 60–62.
- Machin, G.A. 1993. Conjoined twins: implications for blastogenesis. *Birth Defects: Original Article Series*; **29**:141–179.
- Unver, O., Kılınç, M. and Ozyurtlu, N. 2007. Cranial duplication (dicephalus) in a lamb. *Turk. J. Vet. Anim. Sci.*, **31**: 415–417.
- Gulbahar, M.Y., Yuksel, H., Soyguder, Z. and Erçin, O.F. 2005. Dicephalus, Arnold–Chiari malformation, spinal dysraphism and other associated anomalies in a newborn Holstein Calf. *Turk. J. Vet. Anim. Sci.*, **29**: 565–570.
- Monfared, A.L., Sahar, H.N. and Mohammad, T.S. 2013. Case Report of a Congenital Defect (Dicephalus) in a Lamb. *Global Veterinaria*, **10**(1): 90-92.
- Mukaratirwa, S. and Sayi, S.T. 2006. Partial facial duplication (diprosopus) in a goat kid. *Journal of the South African Veterinary Association*, **77**(1): 42-44.
- Salami, O.S., Okaiyeto, S.O., Danbirni, S., Ibe, C., Allam, L. and Kudi, A.C. 2011. A case of diprosopus nauchenos in a day old calf (White Fulani × Friesian cross) in an integrated dairy farm. *International Journal of Livestock Production*, **2**: 55-58.
- Shukla, S.P., Mudasir, Q. and Nema, S.P. 2011. Dystocia due to a cojoined twin monster fetus in a female buffalo. *Buffalo Bulletin*, **30**: 12-13.
- Gungor, O., Yıldız, S. and Colak, A. 2004. Dicephalus in a calf. *Vet. Hek. Dern. Derg.*, **75**: 34-35.
- Dennis, S.M. and Leipold, H.W. 1986. Congenital and inherited defects in sheep. In: D.A. Morrow. Ed., *Current Therapy in Theriogenology* 2nd edn. W.B. Saunders Company, Philadelphia, pp. 864-867.