

## Ultrasonographic Diagnosis and Clinical Management of Pseudopregnancy in Goats

Amarjeet Bisla<sup>1\*</sup>, Brijesh Kumar<sup>2</sup>, Dushyant Yadav<sup>3</sup>, Rohit Satish Kurhe<sup>1</sup>, Javid Ahmad Khan<sup>1</sup>, Athanas Alex Ngou<sup>1</sup>, Rupali Rautela<sup>3</sup> and Harendra Kumar<sup>4</sup>

<sup>1</sup>MVSc Scholar, Division of Animal Reproduction, ICAR-IVRI, Izatnagar, Bareilly-243122, (UP), India

<sup>2</sup>Scientist, Division of Animal Reproduction, ICAR-IVRI, Izatnagar, Bareilly-243122, (UP), India

<sup>3</sup>PhD Scholar, Division of Animal Reproduction, ICAR-IVRI, Izatnagar, Bareilly-243122, (UP), India

<sup>4</sup>Principal Scientist and Head, Division of Animal Reproduction, ICAR-IVRI, Izatnagar, Bareilly-243122, (UP), India

\*Corresponding author: amarjeetbisla@gmail.com

### ABSTRACT

Hydrometra, a synonymous of pseudopregnancy is a major cause of infertility in goats with varying incidences ranging from 1.37-20%. Four pluriparous goats were presented to the referral VGO polyclinic with the history of mating, nearly completed or prolonged gestation period, varying degree of abdominal distension and no signs of imminent kidding. The ultrasonography and X-ray examination revealed that animals were non-pregnant and contain hypoechoic fluid in the uterus. The cases were diagnosed as hydrometra and treatment consisting of cloprostenol sodium (PGF<sub>2</sub>α analogue), valethamate bromide, estradiol benzoate along with dexamethasone was given for evacuation of the uterine contents. All of the animals responded to treatment about 18-20 h later with varying success in uterine evacuation. Thus, the present article highlights the ultrasonographic diagnosis and therapeutic management of hydrometra in goats.

**Keywords:** Pseudopregnancy, Goat, Hydrometra, Cloudburst, Missing kids, Cloprostenol

Pseudopregnancy also known as “hydrometra” or “cloudburst” in goats is the accumulation of sterile secretions within the uterine lumen with unknown etiology and pathophysiology (Purohit and Mehta, 2012). It is the most frequent non-infectious cause of infertility or subfertility in dairy goats (Kornalijnslijper *et al.*, 1997) with an incidence ranging of 1.37-20% in various herds worldwide (Mialot *et al.*, 1991; Hessenlink *et al.*, 1993; Griffiths *et al.*, 2006; Barna *et al.*, 2017; Desire *et al.*, 2017; Maia *et al.*, 2018; Almubarak *et al.*, 2018). Hydrometra in goat is always found to be associated with high progesterone levels secreted by persistent corpus luteum (CL), cessation of cyclical activity, variable degree of abdominal distension and absence of fetal

parts and membranes (Pieterse and Taverne, 1986; Smith, 2009). Pseudopregnancy in goats occurs both after mating and without mating. After mating fertilization followed by embryonic death, persistence of CL may lead to enlargement of abdomen, some degree of udder development which usually lasts for duration of gestation period or longer till regression of CL leading to evacuation of large amount of cloudy fluid. It can also occur when doe was in estrus and not mated, there is cessation of cyclical ovarian activity but there is no marked hydrometra and at the end of period of acyclicity, affected does expel a bloody discharge (Smith, 1986). The disease occurs in older does mostly and is uncommon in yearlings (Smith, 2009) causing

major economic losses to small and marginal livestock owners. Since the introduction of ultrasonography (USG) for pregnancy detection, the goats are easily differentially diagnosed with hydrometra, but without this technique, females with marked abdominal distension are recognized with hydrometra only because of lack of kidding at the expected time (Pieterse and Taverne, 1986; Smith and Sherman, 2009). Although no other complications in female health have been observed, hydrometra certainly impairs the reproductive performance of dairy goats (Mortel, 2001). This study consists of varying degree of hydrometra in four goats presented to VGO polyclinic of the institute, their diagnosis using USG, successful treatment with combination therapy of Prostaglandin  $F_2\alpha$ , Valethamate bromide, Estradiol valerate and Dexamethasone with future reproductive performance follow-up.

The four pluriparous goats of varying age and parity were presented to the Referral Veterinary Polyclinic of the institute with history of normal appetite, mating with prolonged or normally completed gestation periods, varying degree of gradual abdominal distension, with/without cervical discharge where owners were complaining about no kidding even the gestation period completed or prolonged. The particulars of all animals with general and gynecological examination are listed in Table 1.

After taking proper history of animals, the animals were underwent X-ray and per-rectal USG examination which revealed that there were no fetal structures in the womb of the goats. The uterus of the animals were distended with varying degree and USG findings revealed presence of anechoic to hypoechoic fluid. The history along with the clinical examinations of the animals confirmed that these were the cases of hydrometra.

The confirmation of hydrometra after USG findings was followed by treatment *viz.*, three animals were given treatment consisting of cloprostenol sodium (Vetmate<sup>®</sup>-Cargill, India)

250 micrograms IM along with estradiol benzoate (Estogen<sup>®</sup>) 5 mg IM and Valethamate bromide (Epidocin<sup>®</sup>-TTK, India) 16 mg IM and dexamethasone (Dexona<sup>®</sup>- Zydus, India) 2.5 mg IM, while animal no. 2 which was already having the cervical discharge, given only cloprostenol sodium (Vetmate<sup>®</sup>-Cargill, India) 250 micrograms IM with dexamethasone (Dexona<sup>®</sup>- Zydus, India) 2.5 mg IM. All of the animals started evacuation of cloudy watery fluid within 24 h of the therapy. One of the animals (no. 3) was having severe abdominal distension and as the evacuation of fluids was not completed even after 3 days so the same therapy was repeated again and the animal evacuated around a total of 4-5 litres of fluid. The cases were followed upto 2 months of the therapy and only one animal came in estrus after about 20 days of treatment while rest did not show any estrus behaviour.

The treatment of hydrometra involves emptying of the uterus usually by one or two parenteral administrations of  $PGF_2\alpha$ , (Pieterse and Taverne, 1986). In this study, in addition to prostaglandin  $F_2\alpha$  analogue, estradiol benzoate and valethamatebromide were also given to three animals for the cervical ripening and dilatation.  $PGF_2\alpha$  is given as a resort of treatment because of its ability to do luteolysis followed by cervical dilatation and evacuation of uterine contents. In some females, however, complete drainage of the fluid was not achieved after the use of two doses of  $PGF_2\alpha$  (Souza *et al.*, 2013) which is also true in this study where one animal did not evacuate completely. In this study re-initiation of reproductive cycles does not occur following treatment as reported previously by various workers (Pieterse and Taverne, 1986; Martel, 2001; Souza *et al.* 2013). This may also be attributed to the season because the cases were presented in the month of May and June which is not the actual breeding season of the goat (Short day breeders).

Maia *et al.* (2018) reported that three doses of d-cloprostenol alone at an interval of 10 days were effective for the complete drainage

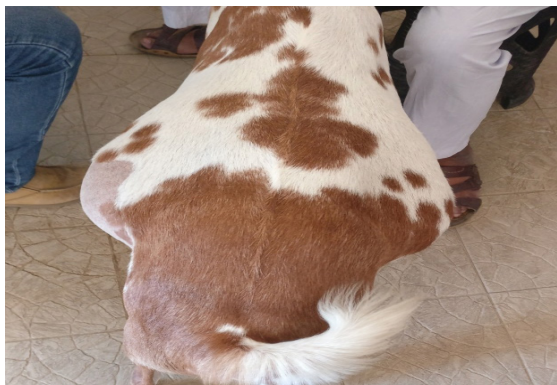**Table 1:** Particulars of goats after general and gynecological examination

Particulars	Animal no. 1	Animal no. 2	Animal no. 3	Animal no. 4
Age	10 years	6 years	3.5 years	5 years
Parity	7 <sup>th</sup>	5 <sup>th</sup>	3 <sup>rd</sup>	4 <sup>th</sup>
Rectal temperature (°F)	102	102.5	102	103
Gestation length (Days after mating)	7 months	5 months 15 days	5 months	5 months 10 days
Respiratory distress	Slight	Moderate	Moderate	Moderate
Severity of abdominal distension	Less	Moderate	Severe	Severe
Appearance of distension from back of the doe	Not much appreciable	Not much appreciable	Bilateral (Pear shape)	Bilateral (Pear shape)
General body condition	Good	Moderate	Well fed (fatty)	Well fed (fatty)
Patency of cervix	Cervix closed; No history of vaginal discharge	Cervix open; History of watery vaginal discharge from last 3-4 days	Cervix closed; No history of vaginal discharge	Cervix closed; No history of vaginal discharge
X-ray findings	No fetal structures seen	No fetal structures seen	No fetal structures seen	No fetal structures seen
Per-rectal USG findings	Moderate level distension of uterine lumen filled with anechoic to hypoechoic fluid with no fetal structures	Distension of uterine lumen filled with anechoic fluid with no visible fetal structures or placentomes	Extensive distension of uterine lumen filled with anechoic fluid with no visible fetal structures or placentomes	Extensive distension of uterine lumen filled with anechoic fluid with no visible fetal structures or placentomes
Ovary for presence of CL	Not visualized may be distension	Not visualized	Not visualized	Not visualized
Treatment	Cloprostenol sodium (Vetmate®) 250 ug I/M Valethamate bromide (Epidocin®) 16 mg I/M Estradiol benzoate (Estogen®) 5 mg I/M Dexoamethasone (Dexona®- Zydus, India) 2.5 mg I/M	Cloprostenol sodium (Vetmate®) 250 ug I/M Dexoamethasone (Dexona®- Zydus, India) 2.5 mg I/M	Cloprostenol sodium (Vetmate®) 250 ug I/M Valethamate bromide (Epidocin®) 16 mg I/M Estradiol benzoate (Estogen®) 5 mg I/M Dexamethasone (Dexona®- Zydus, India) 2.5 mg I/M	Cloprostenol sodium (Vetmate®) 250 ug I/M Valethamate bromide (Epidocin®) 16 mg I/M Estradiol benzoate (Estogen®) 5 mg I/M Dexoamethasone (Dexona®- Zydus, India) 2.5 mg I/M
Quantity of fluid evacuate	~500 mL	1-1.5 L	4-5 L	4-5 L
Start of response to therapy	24 h	Discharge was present already but quantity increased after the treatment	18 h	20 h
Repetition of treatment	No	No	Yes, same as the previous treatment after 3 days	No
Follow-up	Animal came in estrus after ~ 20 days of treatment. No breeding done	No estrus after treatment	Animal sold after treatment	No estrus after treatment

of uterine contents with USG found as a promising technique in differentiating various degree of hydrometra in goats while Barna *et al.* (2017) found double injection of PGF<sub>2</sub>α at 11 days interval as successful treatment of hydrometra followed by 64% subsequent pregnancy rate. Hydrosalpinx had also been reported concomitantly with hydrometra, which may be a cause of fetal loss after and failure of implantation leading to accumulation of fluid in the uterus (Strandell, 2000; Margalioth *et al.* 2006; Maia *et al.* 2018). Almubarak *et al.* (2016); Farliana and Yimer (2016) and Balamurugan *et al.* (2018) also diagnosed hydrometra in a goat via USG with subsequent use of single injection of cloprostenol sodium for evacuation of uterine contents and returning of the goat to estrus 36 h following the therapy.



**Fig. 1:** Animal no. 1 presented to VGO polyclinic



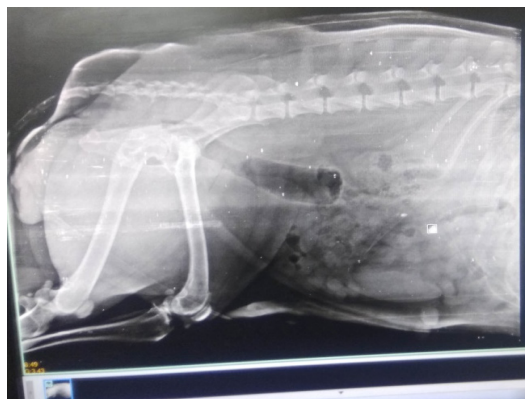
**Fig. 2:** Animal no. 3 presented to VGO polyclinic with moderate abdominal distension



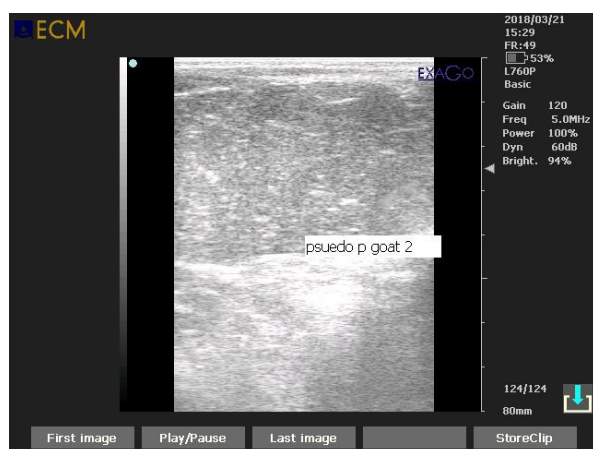**Fig. 3:** Animal no. 4 presented to VGO polyclinic with severe abdominal distension



**Fig. 4:** Animal no. 1 presented to VGO polyclinic with mucoid vaginal discharge after treatment



**Fig. 5:** Radiographic image of animal 1 with hydrometra



**Fig. 6:** Per rectal ultrasonographic image of animal 1 with hydrometra

### SUMMARY

It has been concluded from the present study that USG is a promising diagnostic tool for the diagnosis of hydrometra in goats. The simultaneous use of cloprostenol sodium, valemthamatebromide and estradiol benzoate is also a good therapeutic regimen for early clinical management of the pseudopregnancy in goats.

### ACKNOWLEDGEMENTS

The authors are thankful to the Director, ICAR-Indian Veterinary Research Institute, Izatnagar; Incharge, RVP and Head, Division of

Animal Reproduction for providing necessary facilities in the Referral Veterinary Polyclinic for treatment of animals of poor farmers suffering from obstetrical disorders.

### REFERENCES

- Almubarak, A.M., Abass, N.A., Badawi, M.E., Ibrahim, M.T., Elfadil, A.A. and Abdelghafar, R. M. 2018. Pseudopregnancy in goats: Sonographic prevalence and associated risk factors in Khartoum State, Sudan. *Vet. World*, **11(4)**: 525-529.
- Almubarak, A.M., Abdelghafar, R.M. and Badawi, M.E. 2016. Hydrometra in a Goat - Diagnosis, Treatment and Subsequent Fertility. *Int. J. Liv. Res.*, **6(4)**: 114-118.
- Balamurugan, B., Kumar, A., Ramamoorthy, M. and Ali, A. 2018. Successful Therapeutic Management of Hydrometra in a Doe- A Case Report. *Int. J. Curr. Microbiol. App. Sci.*, **7(07)**: 2044-2047.
- Barna, T., Apić, J., Bugarski, D., Maksimović, N., Mašić, A., Novaković, Z. and Milovanović, A. 2017. Incidence of hydrometra in goats and therapeutic effects. *Arhiv Veterinarske Medicine*, **10(1)**:13-24.
- Desire, S., Mucha, S., Coffey, M., Mrode, R., Broadbent, J. and Conington, J. 2017. Pseudopregnancy and a seasonal breeding in dairy goats: genetic basis of fertility and impact on lifetime productivity. *Animal*, **12**: 1799-1806.
- Farliana, M.D.N. and Yimer, N. 2016. Pseudopregnancy in a Doe and its Hormonal Therapy. *Int. J. Liv. Res.*, **6(6)**: 90-95.
- Hesselink, J.W. 1993. Incidence of hydrometra in dairy goats. *Vet. Rec.*, **132**: 110-112.
- Kornalijnslijper, J.E., Kemp, B., Bevers, M.M., VanOord, H.A. and Taverne, M.A.M. 1997. Induction of hydrometra in goats by means of active immunization against PGF<sub>2</sub>α. *Anim. Reprod. Sci.*, **46**: 109-122.
- Maia, A.L.R.S., Brandão, F.Z., Souza-Fabjan, J.M.G., Veiga, M.O., Balara, M.F.A., Facó, O. and Fonseca, J.F. 2017. Transrectal ultrasound evaluation in tropical dairygoats: an indispensable tool for the diagnosis of reproductive disorders. *Trop. Anim. Health Prod.*, **50**: 787-792.
- Margalioth, E.J., Ben-Chetrit, A., Gal, M. and Eldar-Geva, T. 2006. Investigation and treatment of repeated implantation failure following IVF-ET. *Hum. Reprod.*, **21**: 3036-3043.

- Martel, J.L.M. 2001. Incidencia de la hidrómetra en la Agrupación Caprina Canaria. *Vector Plus*, **6**: 28-34.
- Mialot, J.P., Saboureau, L., GuCraud, J.M., Prengere, E., Parizot, D., Pirot, G., Duquesnel, R., P&at, M. and Chemineau, P. 1991. La pseudogestation chez la chevre. *Rec. Med. Vet.*, **167**: 383-390.
- Pieterse, M. and Taverne, M. 1986. Hydrometra in goats: Diagnosis with real-time ultrasound and treatment with prostaglandin or oxytocin. *Theriogenology*, **26**: 813-821.
- Purohit, G.N. and Mehta, J.S. 2012. Hydrometra in goats (*Capra hircus*): Clinical analysis of 26 cases. *Ruminant Science*, **1(2)**: 117-119.
- Smith, K.C. 2009. Infertility in the ewe and doe (Female Goat). In: Veterinary Reproduction and Obstetrics, Noakes, D. E., Parkinson, T. J. and England, G.C.W., 9<sup>th</sup>. ed. Harcourt Pvt. Ltd.: India; pp. 570-571.
- Smith, M.C. 1986. Caprine reproduction. In: Current Therapy in Theriogenology, Morrow, D.A. 2<sup>nd</sup> ed. W.B. Saunders Company: Philadelphia; pp. 575-629.
- Smith, M.C. and Sherman, D.M. 2009. Goat Medicine. Wiley Blackwell, Iowa.
- Souza, J., Maia, A., Brandao, F., Vilela, C., Oba, E., Bruschi, J. and Fonseca, J. 2013. Hormonal treatment of dairy goats affected by hydrometra associated or not with ovarian follicular cyst. *Small Rumin. Res.*, **111**: 104-109.
- Strandell, A. 2000. The influence of hydrosalpinx on IVF and embryo transfer: a review. *Hum. Reprod. Update*, **6**: 387-395.