



Comparison of Right Flank and Caudal Midline Approaches for Ovariectomy in Gilts

Analisha Debbarma¹, Basanta Saikia^{1*}, Bedanga Konwar¹, Kalyan Sarma²,
Rahul Paul¹ and Nirmali Sarma¹

¹Department of Veterinary Surgery and Radiology, College of Veterinary Sciences & Animal Husbandry, Central Agricultural University, Selesih, Aizawl, Mizoram, India

²Department of Veterinary Medicine, College of Veterinary Sciences & Animal Husbandry, Central Agricultural University, Selesih, Aizawl, Mizoram, India

*Corresponding author: bsbasanta@rediffmail.com

ABSTRACT

To evaluate the two different approaches to accomplish ovariectomy in gilts was used. The animals were randomly divided into two equal (n = 6) groups of Flank and Midline. Ovariectomy was performed by the right flank approach in group flank and by the caudal midline approach in group Midline. In the present study surgical, physiological, haematological parameters, postoperative pain scoring, healing time and wound score were assessed. Bleeding was noticed in group Flank compared to group Midline due to surgical trauma to the muscles. The duration of surgery was 43.33±4.08 and 55.83±5.84 minutes and length of surgical incision was 5.03±0.37 and 5.87±0.35 cm in Group Flank and Midline respectively. Post-operative swelling and erythema were noticed in group Flank compare to group Midline. The time taken for the surgical wound to heal was 9.33±0.81 and 10.83±0.75 days in group Flank and group Midline respectively. There was no significant variation in physiological parameters like heart rate, respiratory rate and rectal temperature in both the groups and within the groups of different periods. There was no significant variation in haematological parameters like haemoglobin and PCV in both the groups except for TLC in group Midline. Based on the observations and evaluation made during the present study, it was concluded that no clinical and haematological alterations were observed in gilts undergoing open ovariectomy (OVE) through the caudal midline and right flank approach. Therefore, both the right flank and caudal midline approaches could be implemented effectively for ovariectomy in gilts. However, the flank approach was less time consuming and the length of surgical incision was comparatively less to the caudal midline approach. Hence, the results show that the right flank approach can be a good alternative to the caudal midline approach for ovariectomy in gilts.

Keywords: Ovariectomy, Right flank, Caudal midline, Haematological, Post-operative pain scoring, Healing time, Wound scoring

Ovariectomy in a pig is a very common surgical procedure in Mizoram and it was reported that the ovariectomized pigs grow better, yielding improved quality meat (Saikia *et al.* 2013). Conventional OVE (COVE) in pig mostly is achieved through caudal midline celiotomy for an easy approach to both the ovaries. But on caudal midline celiotomy, there is a high possibility for post-operative incisional hernia.

The incidence of the evisceration of abdominal organs or other catastrophic consequences is more in ventral midline incision as compared to the flank approach due to the breakdown of incision line because gravitational forces exerted on midline incision (McGrath *et al.* 2004). In addition to this, in the state of Mizoram ventral midline incisional hernia mostly encountered as a postoperative complication of spaying (Saikia

et al., 2009). Thus lateral flank approach was proposed as an alternative to the conventional ventral midline ovariectomy.

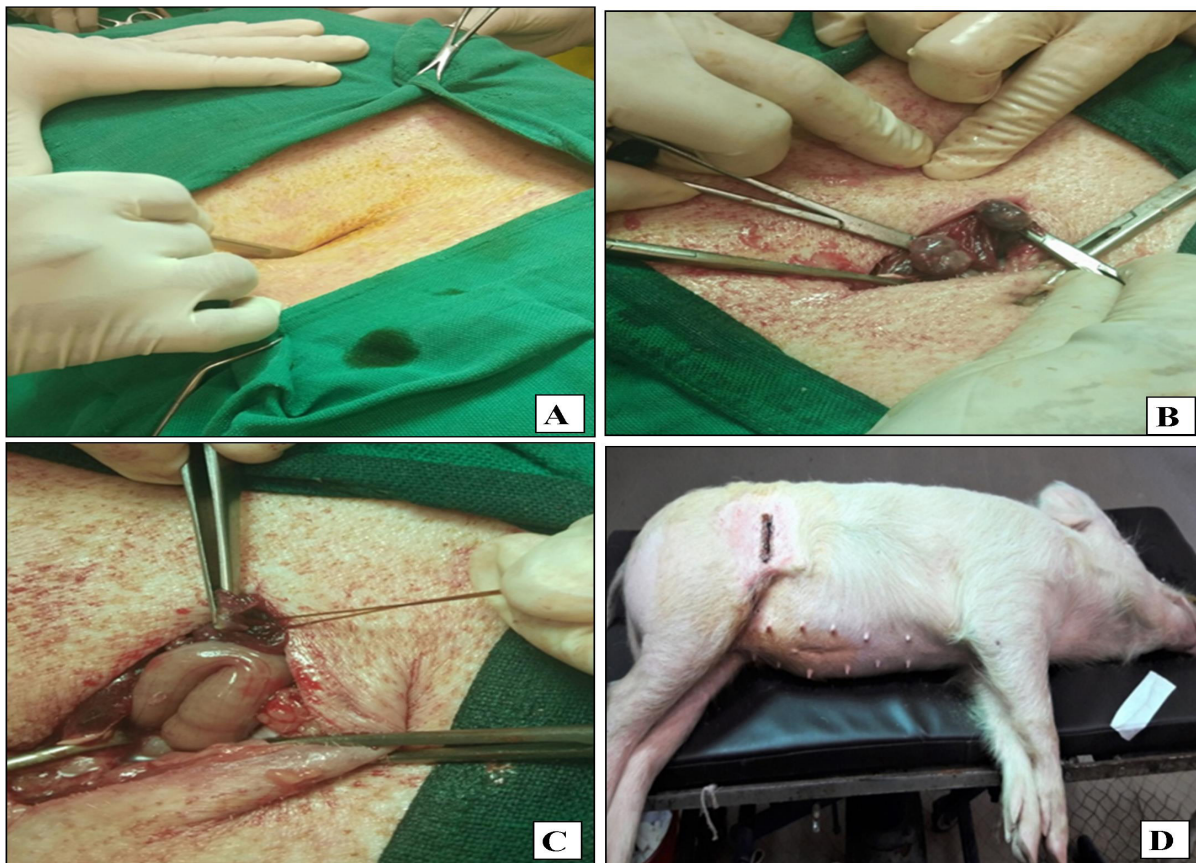
MATERIALS AND METHODS

Twelve healthy gilts were brought to Teaching Veterinary Clinical Complex, College of Veterinary Sciences & Animal Husbandry, Central Agricultural University, Selesih, Aizawl, Mizoram for ovariectomy which was randomly divided into two groups viz. Group Flank and Group Midline and each groups consisting of six animals. The animals in both groups were preanaesthetized by Diazepam @2mg/kg BW, I/V and then anaesthetized by Ketamine@15mg/kg BW, I/V (Konwar and Saikia, 2006).

Surgical Procedure

(A) Right flank approach

After preparing the surgical site on the right flank region, the animals were controlled on left lateral recumbency and incision was made on the right flank position in a dorsoventral direction 2 to 3 cm below the transverse process of lumbar vertebrae (Fig.1A). Once the abdomen had been opened, most of the time the ovary or uterine horn was exposed just below the incision. The ovary or uterine horn was grasped with forceps and delivered through the incision similar to the ventral midline approach. The uterine horn was elevated to expose the bifurcation and contra-lateral uterine horn, which was grasped



(A) Right flank incision; **(B)** Gain exposure to ovaries by applying traction; **(C)** Checking for haemorrhage; **(D)** After a complete surgical procedure

Fig. 1: Right flank surgical approach

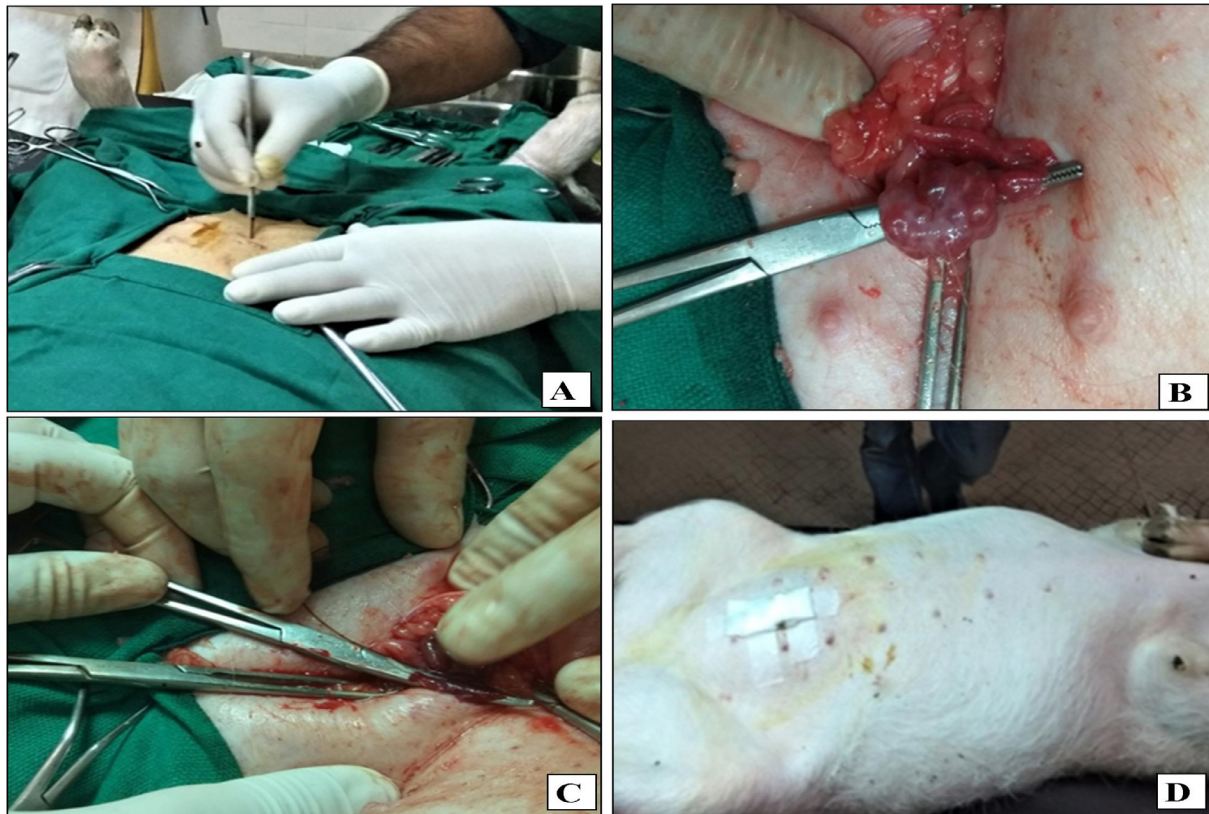


and traced cranially until the ovaries were identified (Fig.1B). The ovarian pedicles were ligated and the ovary was severed distal to the sutures and checked for hemorrhage (Fig.1C). After removal of both the ovaries, peritoneum, muscle, subcutaneous was sutured. And finally, closure of skin incision was done by interrupted horizontal mattress sutures using 2-0 nylon monofilament (Fig.1D).

(B) Caudal Mid ventral approach

Gilts were placed in dorsal recumbency. After the preparation of the surgical site on the ventral midline, a standard skin incision was made in between the last pair of the teat (Fig.2A). Laparotomy was achieved after incising subcutaneous tissue, linea alba, and

peritoneum. A snook ovariectomy hook was used to gain exposure to the uterus and then to each ovary (Fig.2B) by applying traction on the suspensory ligament. A 2-forceps technique was used to ligate each ovarian pedicle with 1 ligature. The pedicle was transected and proper ovarian ligament was ligated with No.2/0 Chromic Catgut. The ovary was severed distal to the sutures and checked for haemorrhage (Fig.2C). After the excision of both ovaries, the uterine body was released into the abdomen. Finally, the peritoneum, linea alba, and subcutaneous tissue were closed by using simple continuous sutures of No.1 Chromic Catgut. Closure of skin incision was done by interrupted horizontal mattress sutures using 2-0 nylon monofilament (Fig.2D).



(A) Caudal Midline incision; **(B)** Gain exposure to ovaries by applying traction; **(C)** Checking for haemorrhage; **(D)** After a complete surgical procedure

Fig. 2: Caudal Midline approach



For comparison of both the surgical procedure following parameters were evaluated:

(A) Surgical parameters

- ❑ **Surgical time:** Times were recorded from the starting of skin incision until complete wound closure in minutes.
- ❑ **Incision length:** Incision length was measured in cm with the help of scale.
- ❑ **Blood loss during operation:** Blood loss was measured as per method described by Eipe and Ponniah (2006).

(B) Physiological parameters: Heart rate (HR) (beats/min), Respiratory rate (RR) (breaths/min) and Rectal temperature (RT) ($^{\circ}$ C) were recorded before administration of anaesthetic agent (before surgery) then every day up to 7th postoperative day.

(C) Haematological study: The blood samples (2ml) were collected from ear veins or anterior vena cava, in dry vials containing K3EDTA before administration of anaesthesia (baseline) (BS), then every day up to 7th postoperative day for the estimation of Haemoglobin (Hb g/dl), Packed Cell Volume (PCV %) and Total Leukocyte Count (TLC $\times 10^3$ /cu.mm) using automated haematology cell counter (MS4e, Netherland).

(D) Post-operative pain scoring: Post-operative pain scoring was done as per the score card described by Viscardi *et al.* (2017) with Piglet Grimace Scale from day 0 to day 7 after the surgery.

(E) Healing time of surgical site (days) and wound scoring: The clinical appearance/ gross changes of the wound were scored at 0 to 14th day post-surgery. The wound was scored based on swelling, erythema, dehiscence, and discharge as suggested by Sylvestre *et al.* (2002).

Statistical analysis was carried out by SPSS version 20 with a one-way Analysis of Variance (ANOVA) and t-test.

RESULTS AND DISCUSSION

(A) Surgical parameters

(i) Surgical time

The mean total surgical time in Group Flank (43.33 ± 4.08) was significantly ($P \leq 0.01$) less as compared to Gr. Midline (55.83 ± 5.84). It might be due to that genital organs could be immediately accessed in the flank method as compared to the ventral midline approach (Hansen, 2005). Similarly, Rana (2007) also reported that the duration of operation was significantly less in cats operated through flank (24 ± 2.65 min) approach than the midline (29 ± 3.51 min).

(ii) Incision length

In regards to surgical incision length, it was observed that group flank was (5.03 ± 0.37 cm) significantly shorter than the midline approach (5.87 ± 0.35 cm). This finding is correlated with Kiani *et al.* (2014). Kiani *et al.* (2014) reported that the subgroup-Fa was incised with a shorter length (2.82 ± 0.13 cm) than that of subgroup-Ma (2.88 ± 0.23 cm) for ovariohysterectomy. It might be because it was easy and convenient to provide better accessibility and localization as compared to the midline approach (Rana, 2007).

(iii) Blood loss during operation

During operation, the mean total blood loss was significantly ($P \leq 0.01$) more in Group Flank (55.83 ± 7.35 ml) as compared to Group Midline (26.83 ± 2.78 ml). This could be due to the presence of high vascular channels in the abdominal muscle mass when compared to poor vasculatures associated with tendon and ligament in the linea alba. This finding was in line with the finding of Abubakar *et al.* (2014).

(B) Physiological parameters: There was no significant variance in heart rate, respiratory



rate and rectal temperature in both the groups in different periods as well as within the groups. This is in line with the observations of Hancock *et al.* (2005), Kumar (2006) and Holey (2010) who have also recorded similar results during their investigation.

(C) Haematological study

The mean values of haemoglobin and PCV recorded in different periods of observation did not show any significant difference ($P > 0.05$) on comparison either between the groups or between the periods in the same groups (Table 1) Values were non-significantly ($P > 0.05$) decreased on day 1 in both the groups as compared to day 0 and then gradually increased towards the baseline value in both the group Flank and group Midline. The results of the present study are in line with the findings of Kumar *et al.* (2014). The decline in the values could be attributed to the splenic pooling of erythrocytes during anaesthesia. (Tiwari, 2015) or might be due to the intraoperative blood loss during the time of surgery (Khandekar, 2011).

The mean values of total leukocyte count recorded in different periods of observation did not show any significant difference ($P > 0.05$) on comparison within the periods in group Flank (Table 1). But significant variations ($P \leq 0.01$) were observed within the periods in group Midline. Also, a significant difference ($P \leq 0.01$) was observed between both the groups except on day 0. In group Midline, total leukocyte count was significantly ($P \leq 0.01$) increased on day 1 as compared to day 0 and then gradually decreased to reach the baseline value on day 7. The results were similar to Laiju *et al.* (2011) and Fazio *et al.* (2015) who also observed in conventional ovariohysterectomy in dogs. Dharmaceelan *et al.* (2000) also reported a significant increase in total leucocyte count on a first post-operative day which might be due to tissue trauma during surgery resulting in increased leucocytes in the peripheral blood and produced stress leukogram pattern (Rebar, 2004) in complete blood count.

(D) Post-operative pain scoring

A significant difference ($P \leq 0.05$) was recorded between the groups on different observations in both group flank and midline (Fig. 3). Significantly decreased ($P \leq 0.05$) mean post-operative pain score was observed in group flank as compared to group midline on Day 0, Day 1, Day 2 and Day 3 and non-significantly decreased ($P > 0.05$) value was observed on all other periods of observation. This finding is almost as per Viscardi *et al.* (2017). Any difference in post-operative pain between two approaches might be due to differences in the sensitivity of the skin of the flank and midline region (Burrow *et al.* 2005). Considering the results it could also be due to gravitational forces acted upon abdominal organs exerted on caudal midline incision are higher than those on the right flank incision.

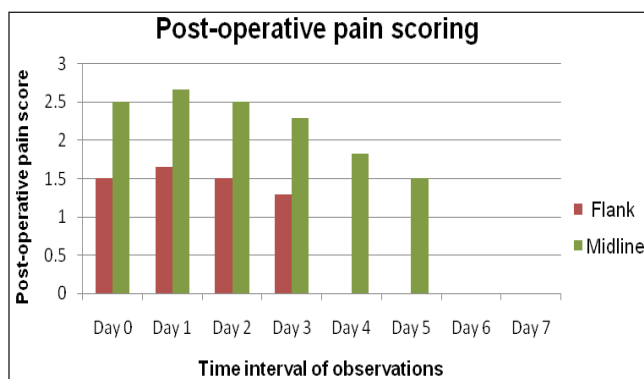


Fig. 3: Mean \pm SD values of post-operative pain score in right flank & caudal midline approach for ovariectomy

(E) Healing time of surgical site (days) and wound scoring

The mean healing time of the surgical site was significant ($P \leq 0.05$) less in Group Flank (9.17 ± 0.75 days) than Group midline (10.17 ± 1.47 days). Similar results were observed by Kiani *et al.* (2014) and Rana (2007) who also reported that wound healing was better and faster in the flank approach as compared to the ventral midline approach. Non-significant faster healing

Table 1: Mean \pm SD values of Hb, PCV and TLC in right flank & caudal midline approach for ovariectomy

Groups	Hb (gm/dl)		PCV (%)		TLC (%)	
	Flank	Midline	Flank	Midline	Flank	Midline
Day 0	11.20 \pm 0.55	11.71 \pm 0.90	40.90 \pm 0.89	40.94 \pm 1.89	16.07 \pm 2.30	14.30 \pm 0.70 ^b NS
Day 1	10.86 \pm 0.50	11.16 \pm 0.32	40.88 \pm 0.61	40.70 \pm 1.58	17.28 \pm 0.70	14.54 \pm 0.83 ^{b**}
Day 2	10.86 \pm 0.39	11.18 \pm 0.44	40.05 \pm 1.46	40.63 \pm 1.62	16.65 \pm 0.40	13.76 \pm 0.80 ^{ab**}
Day 3	10.98 \pm 0.25	11.23 \pm 0.44	39.81 \pm 0.79	39.33 \pm 2.60	16.08 \pm 0.86	13.32 \pm 0.53 ^{a**}
Day 4	11.01 \pm 0.28	11.35 \pm 0.62	39.96 \pm 1.14	40.40 \pm 1.20	16.30 \pm 0.95	13.26 \pm 0.48 ^{a**}
Day 5	11.15 \pm 0.38	11.43 \pm 0.95	40.01 \pm 1.49	40.50 \pm 1.02	15.99 \pm 1.44	13.36 \pm 0.45 ^{a**}
Day 6	11.28 \pm 0.31	11.61 \pm 1.05	40.36 \pm 1.17	40.63 \pm 1.13	16.17 \pm 1.04	13.77 \pm 0.54 ^{ab**}
Day 7	11.30 \pm 0.32	11.75 \pm 1.02	41.56 \pm 0.85	41.51 \pm 1.69	16.64 \pm 1.02	13.88 \pm 0.77 ^{ab**}
Significance	NS	NS	NS	NS	NS	**

(** $P \leq 0.01$ = Significant at 1%; NS= Non-significant; Means bearing similar lowercase superscript in the same row do not differ significantly).

Table 2: Mean \pm SD values of wound scoring in right flank & caudal midline approach for ovariectomy

DURATION	Group (n=6)	Swelling (Mean \pm SD)	Erythema (Mean \pm SD)
18-24 hrs	Flank	0.83 \pm 0.75	0.84 \pm 1.16
	Midline	0.50 \pm 0.54	0.67 \pm 0.81
Significance		NS	NS
10-14 days	Flank	0.66 \pm 0.51	0.33 \pm 0.52
	Midline	0.33 \pm 0.51	0.16 \pm 0.40
Significance		NS	NS

in the flank approach in the present study as compared to the midline approach might be due to smaller incision and better circulation of muscles of the flank area as compared to linea alba.

The wound was recorded based on swelling and erythema (Table 2) and was scored at 2-time points: 18 to 24 hrs and 10 to 14 days post-surgery. No significant difference ($P > 0.05$) was found between the groups for both swelling and erythema. In the present study, a non-significant difference of swelling and erythema both at 18-24 hrs and 10-14 days after surgery with flank approach having the highest score and this might be a result of surgical trauma caused by the traumatic surgical instruments on the soft tissue in the course of surgery. This finding is consistent with the studies conducted

by Sylvestre *et al.* (2002) and Abubakar (2012) where significant differences among the variables were observed.

CONCLUSION

Considering all these observations from the present study, it is concluded that no clinical and haematological alterations were observed in gilts undergoing conventional open ovariectomy (COVE) through the caudal midline and right flank approach. Therefore, both the right flank and caudal midline approaches could be implemented effectively for ovariectomy in gilts. However, the right flank approach for ovariectomy was found to be better in terms of operative timing, incisional length, pain and healing over the caudal midline approach.



REFERENCES

- Abubakar, A.A., Adeyanju, J.B., Kene, R.O.C., Sonfada, M.L., Yakubu, A.S., Adamu, U. and Sahabi, S.M. 2012. Evaluation of three suture techniques based on surgical wound assessment in Caprine. *Scientific Journal of Veterinary Advances*, **1**(4): 101-104.
- Abubakar, A.A., Andeshi, R.A., Yakubu, A.S., Lawal, F.M. and Adamu, U. 2014. Comparative Evaluation of Midventral and Flank Laparotomy Approaches in Goat. *Journal of Veterinary Medicine*, Article ID 920191, pp- 6.
- Burrow, R., Batchelor, D. and Cripps, P. 2005. Complications observed during and after ovariohysterectomy of 142 bitches at a veterinary teaching hospital. *Veterinary Record*, **157**(26): 829-833.
- Dharmaceelan, S., Ganesh, T.N. and David, W.P.A. (2000). Laparoscopic sterilization in bitches: comparison of three techniques. *Indian J. Vet. Surg.*, **21**(2): 65-68.
- Eipe, N. and Ponniah, M. 2006. Perioperative blood loss assessment- how accurate? *Indian J. Anaesth.*, **50**(1): 35-38.
- Fazio, E., Medica, P., Cravana, C., Pupillo, A. and Ferlazzo, A. 2015. Effects of ovariohysterectomy in dogs and cats on adrenocortical, haematological and behavioural parameters. *Acta Scientiae Veterinariae.*, **43**(1339): 1-8.
- Hancock, R.B., Lanz, I., Waldron, D.R., Duncan, R.B., Broadstone, R.V. and Hendrix, P.K. 2005. Comparison of postoperative pain after ovariohysterectomy by harmonic scalpel assisted laparoscopy compared with medianceliotomy and ligation in dogs. *Vet. Surg.*, **34**: 273-282.
- Hansen, M. 2005. Flank cut as an alternative to the linea-alba incision at ovariohysterectomy of female. *Swedish University of Agriculture and Animal Science, Uppsala*, **22**: 234-245.
- Holey, S.A. 2010. Comparison of laparoscopic electro-coagulation and endo-stapling techniques of ovariohysterectomy in female dogs. M.V.Sc. Thesis, Submitted to Karnataka Veterinary, Animal and Fisheries Science University, Bidar, India.
- Khandekar, G.S. 2011. Laparoscopic examination and treatment of abdominal disorders in dogs and pigs. Ph.D. Thesis, Submitted to Maharashtra Animal and Fishery Sciences University, Nagpur.
- Kiani, F.A., Kachiwal, A.B., Shah, M.G., Nizamani, Z.A., Khand, F.M., Lochi, G.M., Haseeb, A., Khokhar, A.M., Oad, A. and Ansari, M.I. 2014. Comparative Study on Midline and Flank Approaches for Ovariohysterectomy in Cats. *Journal of Agriculture and Food Technology*, **4**(2): 21-31.
- Konwar, B. and Saikia, B. 2006. Ketamine and its combination with diazepam for balanced anaesthesia in swine. *Indian Vet. J.*, **83**(5): 507-508.
- Kumar, A., Singh, Sukhbir and Chaudhary, R.N. 2014. Evaluation of diazepam-ketamine as anaesthetic combination in buffalo calves. *Haryana Vet.*, **53**(1): 58-62.
- Kumar, S.S.S. 2006. Comparison of surgical and laparoscopic method of sterilization in bitches. M.V.Sc. thesis, Karnataka Veterinary, Animal and Fisheries Science University, Bidar, India.
- Laiju, M.P., Devanand, C.B. and Sarada A.T. 2011. Effect of surgical stress on physiological, haematological and biochemical parameters in elective canine ovariohysterectomy. *JIVA.*, **9**(1): 25-27.
- McGrath, H., Hardie, R.J. and Davis, E. 2004. Lateral flank approach for ovariohysterectomy in small animals. *Compend. Contin. Educ. Small Anim. Pract.*, **26**: 922-930.
- Rana, M.A. 2007. Comparative study of flank vs midline approach for ovariohysterectomy in cats. UVAS, Lahore (Pakistan), pp. 75.
- Rebar, H.A. 2004. Hemogram interpretation for dogs and cats. Gloyd, Group, Wilmington, U.S.A., pp. 35.
- Saikia, B., Konwar, B. and Sarma, K. 2009. Comparison of three surgical approaches for correction of ventral hernia in pigs. *Indian Vet. J.*, **86**: 752-753.
- Saikia, B., Konwar, B., Bayan, H. and Ahmed, F.A. 2013. Laparoscopic ovariectomy in pigs. *Indian Vet. J.*, **90**(5): 123-124.
- Sylvestre, A., Wilson, J. and Hare, J. 2002. A comparison of 2 different suture patterns for skin closure of canine ovariohysterectomy. *Can. Vet. J.*, **43**: 699-702.
- Tiwari, M.K. 2015. Comparative evaluation of butorphanol tartrate and propofol as constant rate infusion in laparoscopic ovariectomy in canine. M.V.Sc. Thesis, Submitted to Maharashtra Animal and Fishery Sciences University, Nagpur.
- Viscardi, A.V., Hunniford, M., Lawlis, P., Leach, M. and Turner, P.V. 2017. Development of a Piglet Grimace Scale to Evaluate Piglet Pain Using Facial Expressions Following Castration and Tail Docking: A Pilot Study. *Front. Vet. Sci.*, **4**: 51.

